



Histomorphometric Comparison of 3 Osteotomy Techniques

Frederic B. Slete, DDS,* Paul Olin, DDS, MS,† and Hari Prasad, MS‡

The evolution of modern dental implant treatment can be traced to at least 2500 BC with the Egyptian civilization.¹ Throughout this evolution, much time, effort, and research have been directed toward the single root form implant fixture. In the last few decades, an endless array of shapes, grooves, threads, tapers, platforms, surface coatings, alloys, ceramics, etchings, polishes, and designs have been tried, tested, and marketed.^{2,3} All in an effort to gain or increase primary stability and the promise of subsequent secondary stability or osseointegration.

As recently as 1995, it was postulated that in implant dentistry “the system has not been fully optimized.”⁴ Dentistry is still on a quest to achieve and enhance primary stability and thus predictably allow for immediate or earlier loading of implants.

Primary stability of implants is defined as dependent upon bone quality and quantity, implant fixture design, and surgical technique.⁵⁻⁷ The goal of primary stability is achieved when implant micromotion can be limited to

Purpose: This pilot study compares the histomorphometric structure of osteotomy preparation through standard extraction drilling (SD), Summers osteotomes (SO), and a new method of nonextraction drilling called osseodensification (OD).

Method and Materials: Fresh porcine tibia plateau was used as the surgical specimen. Three preparation methods ($N = 6$ for each) were used to prepare 18 osteotomies according to manufacturer protocols. Eighteen tapered screw-vent (4.7×13 mm) implants were placed. After osteotomy preparation and implant placement, all porcine tibias were placed in 10% formalin solution in preparation for histological staining and sectioning. Histomorphometric analysis of all

samples was performed to compare immediate bone-to-implant contact (BIC) and the percentage of bone volume within a 2-mm zone surrounding the implant.

Results: OD achieved 60.3% BIC, SO 40.7% BIC, and standard extraction drilling (SD) 16.3% BIC. The percentage of bone volume in the surrounding 2-mm width from the implant body using the same area units per sample was found to be greatest for OD.

Conclusion: This study demonstrated that osteotomy preparation can influence both BIC and percentage of bone volume around the implant. (*Implant Dent* 2018;27:424-428)

Key Words: osseodensification, BIC, BV%, primary stability

less than 50- to 150- μ m thresholds until osseointegration occurs.⁸⁻¹⁰

The most common osteotomy preparation technique for implant placement is surgical extraction drilling of bone. Commercially available surgical burs are modeled after drill bits or burs designed to cut materials other than bone such as metal or wood.¹¹ These burs, adapted for dental use, produce an osteotomy through removal or extraction of bone tissue to create a “hole” to receive the implant fixture.¹²

Bone preparation without “extraction” drilling can be achieved using osteotomes. This technique was introduced by Summers¹³ in an attempt to increase primary stability and expand the edentulous ridge without the extraction of bone

tissue. Osteotome techniques have been shown to create a layer of compacted bone at the implant interface in the cancellous bone.¹⁴⁻¹⁶ This can enhance primary stability of the implant. However, limitations of this technique include surgical trauma, unintentional fracture or displacement of bone, and even patient vertigo.¹⁷

A new osteotomy technique, as described by Huwais and Meyer,¹⁸ has recently been introduced. This method of osseous densification and bone compaction (osseodensification) occurs without the extraction of the bony matrix, but rather takes advantage of the viscoelastic and plastic abilities of the bone to deform using a time-dependent stress (force) to create a

*Private Practice, Jackson, MI; Graduate, University of Minnesota School of Dentistry Certificate Program in Contemporary, Implant, and Esthetic Dentistry, Minneapolis, MN.

†Associate Professor, Director, Division of Prosthodontics, Department of Restorative Services, Dental Implant Program, University of Minnesota School of Dentistry, Minneapolis, MN.

‡Assistant Director, Hard Tissue Research Laboratory, Senior Research Scientist, University of Minnesota, School of Dentistry, Minneapolis, MN.

Reprint requests and correspondence to: Frederic B. Slete, DDS, 306 W, Washington, Suite 205, Jackson, MI 49201, Phone: 517-787-5055, Fax: 517-787-9346, E-mail: gringuy1@comcast.net

ISSN 1056-6163/18/02704-424

Implant Dentistry

Volume 27 • Number 4

Copyright © 2018 Wolters Kluwer Health, Inc. All rights reserved.

DOI: 10.1097/ID.0000000000000767




Fig. 1. **A**, Three preparation methods with longitudinal section of the implant/bone relationship at day zero, $\times 20$, $\times 50$, and $\times 100$ magnification. The longitudinal section demonstrates that standard drilling produced minimal bone occupancy within the threads. The OD method demonstrates increased unfractured and compacted bone within the threads compared with the osteotome method, which reveals fractured and less dense bone segments. **B**, Three preparation methods' cross-sectional view of implant/bone at day zero, $\times 50$ and $\times 100$ magnification. The center horizontal row is stained with Stevenel's blue and van Gieson's picrofuchsin and analyzed with polarized light. Vital bone (red), nonvital bone (green), and nuclei and cells (blue). Standard drilling produced minimal bone contact with the implant body. The OD method demonstrates intimate contact of compacted bone particles with the implant. The osteotome method produced an irregular contact with the implant and a scattered pattern of compacted fractured trabecular bone segments.

time-dependent strain (deformation).^{18–20} This technique produces a “burnished” crust of increased bone mineral density around the osteotomy site circumferentially and apically.¹⁸

The purpose of this investigation was to compare 3 techniques of osteotomy preparation through analysis of a histological survey for bone-to-implant contact (BIC), bone density, and distribution

immediately surrounding the implant at the time of placement also known as bone volume percentage (BV%), and trabecular integrity after preparation.

MATERIALS AND METHODS

Experimental Design

Commercially available surgical burs were used to prepare the implant osteotomies in the standard drilling (SD) group using the manufacturers' recommendations. This drilling sequence included a pilot drill (1.7 mm) followed by the manufacturers' sequence for the appropriate implant size (4.7 mm). The Summers osteotome (SO) group was prepared with a pilot drill (1.7 mm) followed by consecutive Osteotome compaction to size the osteotomy through instrumentation sizes I, II, III of the set. Osseodensification (OD) was performed through a pilot drill (1.7 mm) and consecutive densification burs with maximum diameters of 2.5, 3.5, and 4.5 mm. Water irrigation was used during preparation.

Specimens

A total of 18 implant sites were prepared in 6 porcine tibia plateau bone samples. The bone samples were prepared by removing the articular surface and subchondral layers to expose the cancellous bone. Groups of 3 osteotomies were randomly prepared in each tibia, using the 3 preparation techniques. Care was taken to place each osteotomy outside the central softer medullary area of the tibia bone. A total of $N = 6$ for each technique was completed. A standardized 4.7mm \times 13mm tapered screw-vent implant was fully seated in each osteotomy immediately upon completion of osteotomy preparation.

Histologic Preparation and Quantitative Analysis

The specimens were harvested and placed in 10% neutral buffered formalin immediately upon implant placement. Upon receipt in the Hard Tissue Research Laboratory at the University of Minnesota, the implant and bone specimen were sectioned vertically in an anterior/posterior (mesial/distal) orientation according to protocol specifications.

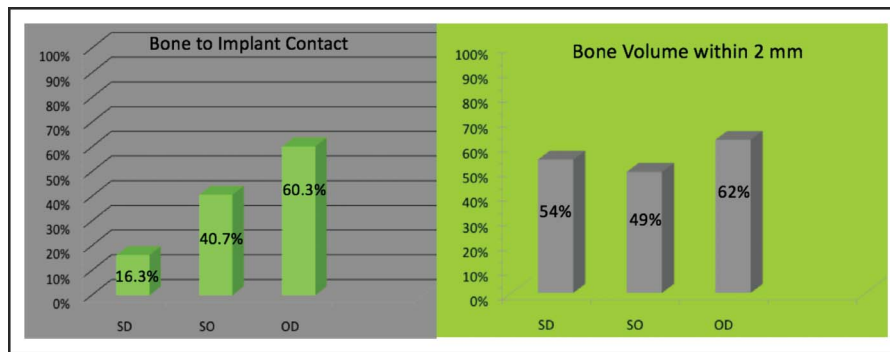


Fig. 2. Graphic representation of computerized image analysis of vital bone, nonvital bone, and nonbone elements within 2 mm of the implant after preparation through each of the 3 tested methods. BIC and BV% were analyzed and calculated for each method. The OD method improved both the BIC and BV% within 2 mm of the implant versus the other methods tested.

Immediately after sectioning specimens were dehydrated with a graded series of alcohols for 9 days. After dehydration, the specimens were infiltrated with a light-curing embedding resin (Technovit 7200 VLC; Kulzer, Wehrheim, Germany). After 20 days of infiltration with constant shaking at normal atmospheric pressure, the specimens were embedded and polymerized by 450-nm light with the temperature of the specimens never exceeding 40°C. The specimens were then prepared by the cutting/grinding method of Donath and Rohrer.^{21,22}

The specimens were cut to a thickness of 150 μm on an EXAKT cutting/grinding system (EXAKT Technologies, Oklahoma City, OK). Then, specimens were then polished to a thickness of 45 to 65 μm using a series of polishing sandpaper discs from 800 to 2400 grit using an EXAKT microgrinding system followed by a final polish with 0.3- μm alumina polishing paste. The slides were stained with Stevenel's blue and van Gieson's picrofuchsin and cover-slipped for histologic analysis by means of bright field and polarized microscopic evaluation.

This method differentially stains material within the specimens. Very precise determinations of the percentage of vital, nonvital bone, and nonbone components are possible using computerized image analysis.

- Vital bone stains bright red with variations in intensity depending on the maturity of the bone

- Nonvital bone and osteoid stain bright green
- Nuclei of cells, including osteoblasts, osteoclasts, and osteocytes, stain blue
- Connective tissue stains various shades of green.

Histomorphometric Analysis

After histological preparation, the specimens were evaluated histomorphometrically. All the specimens were digitized at the same magnification using a Nikon Eclipse 50i microscope (Nikon Corporation, Tokyo, Japan) and a SPOT Insight 2 mega sample digital camera (Diagnostic Instruments Inc., Sterling Heights, MI). Histomorphometric measurements were completed using a combination of programs of the SPOT Insight 2 mega sample digital camera (Adobe Photoshop, Adobe Systems, and National Institutes of Health [NIH] Image).

At least 2 slides of each specimen were evaluated. Histomorphometric analysis was performed, and the parameters measured were the percentage of total bone area, connective tissue, and marrow space. BIC was also calculated for each specimen evaluated (Fig. 2). Slide magnification views of $\times 20$, $\times 50$, and $\times 100$ were prepared for analysis, observation, and comparison.

RESULTS

In quantifying BIC (Fig. 2), OD preparation produced 60.3%, SO

40.7%, and SD 16.3% of implant perimeter in contact with bone. BV% within 2 mm of the implant (Fig. 2) produced was 62% for OD, 49% for SO, and 54% for standard drilling (SD). It was also noted that the osseodensification (OD) method consistently produced an increase in fine bone particles dispersed within the surrounding marrow spaces and between the implant threads.

DISCUSSION

Comparing the histologic slides in Figure 1, A and B at $\times 100$ magnification, some obvious and significant differences can be observed. The SD (standard drilling) method of preparation produced an implant fixture surrounded by native bone with some trabecular bone contact consistent upon the outer edge or perimeter of the implant threads, with even and undisrupted marrow spaces. There was very little, if any, trabecular bony structure between or in contact with the inner portion of the thread design or implant body core. This was consistent in both the longitudinal and cross-cut implant sections produced (Fig. 1, A and B). The distribution and pattern of the trabecular and marrow space architecture immediately surrounding the implant were unaltered by preparation and implant placement.

In the samples produced through SO, there was visible compression and condensation of the trabecular pattern in the area immediately adjacent and in contact with the implant. Bony contact with the perimeter and intrathread dimensions was enhanced compared with standard drilling (SD). The pattern of compression and condensation was non-uniform longitudinally and in cross-section. Some areas of the implant had a compressed trabecular pattern, and some areas did not, displaying irregular compression patterns. Furthermore, trabecular integrity was compromised consistently in the SO method, evident by the appearance of broken, fractured, and partial piece trabeculae throughout the compressed bony matrix in contact with or near the implant (Fig. 1, A and B). Although the data in this study resulted in a higher bone volume calculated in

the 2-mm zone around the implant through standard drilling (SD) 54% versus SO 49% method (Fig. 2), the histology immediately adjacent and in BIC calculated demonstrates enhanced bony geometry resulting through SO.

In the osseodensification (OD) method, compression and condensation of whole, intact trabeculae was observed surrounding the implant fixture in longitudinal and cross-section specimens (Fig. 1, A and B). Furthermore, bony condensation was also observed at the apical tip of the implant that was not consistently produced through the other 2 methods (Fig. 1A). The resulting compression and condensation of bone was much more consistent and uniform throughout, and the zone of visible compression was consistent at roughly 0.7 mm laterally and apically. The intimacy of BIC is visible at $\times 20$, $\times 50$, and $\times 100$ magnification (Fig. 1, A and B). The completeness of intrathread spaces completely filled by whole, intact trabecular structures should be noted. This is significant clinically in that trabecular bone condensation has been shown to increase primary stability, increase BIC, and accelerate bone healing.^{15,16,23}

Bone mineralization and organic tissue properties along with its architectural distribution determine the mechanical competence properties of bone.²⁴ Therefore, cancellous bone structural stability is directly related to trabecular connectivity, integrity, and thickness.²⁵

Implant stability is affected by the quality of the microstructural bone near the implant. Local bone density has been postulated to be the best single morphometric predictor of implant stability.²⁶ In this study, the osseodensification (OD) method demonstrated a significant increase in the bone volume surrounding the implant, in BIC (Fig. 2), and in structural integrity, and thus lends itself toward enhanced primary stability through a preparation technique, in effect, making a better hole.

These observations and results of trabecular integrity or fracture, depending on the preparation method may extend to the *in vivo* studies that have shown that osteotome compression/expansion through SO results in delayed healing of the osteotomy.^{27,28} The microdamage and trauma produced, as

evident by the resulting fractured and broken trabeculae, may promote a prolonged inflammatory and “clean-up” stage of healing before new bone growth and remodeling can ensue.

In vivo studies on sheep have shown that fine bony particles in the walls of the osteotomy and in between the threads of the implant body act as new bone growth initiators to enhance progression to secondary stability.^{29–31} Furthermore, osteotomy production without extraction of existing bone preserves existing collagen and bone bulk. The presence of collagen and bone bulk enhances revascularization, a critical element in new bone growth and remodeling.⁹

Further investigation into the resulting new bone growth and revascularization after OD is warranted. Investigation into cellular repair mechanisms and bone morphogenic protein timing and response comparing osseodensification versus standard drilling and osteotome preparation would also be beneficial in understanding this new technique.

CONCLUSION

In this study:

- The osseodensification (OD) method of osteotomy preparation produced a higher BIC percentage (BIC%) than did the SO or standard drilling (SD) methods by 50% or more.
- Osseodensification (OD) preparation also resulted in significantly more BV% immediately surrounding the implant.
- The trabecular bone quantity and integrity immediately surrounding the implant appeared visibly more intact, denser, and more consistent in distribution through osseodensification (OD) preparation than the other methods tested. This was evident both laterally and apically to the implant body.
- The osseodensification (OD) method produced the presence of fine bony autogenous graft particles throughout the compacted trabeculae.

Clinical Application

Clinically, the preparation technique could have a significant influence on our ability to more consistently achieve an increase in primary stability on the day of surgery. Bone preparation techniques that promote BIC, BV%, bone quality around the newly placed implant enhance primary stability by definition.

The presence of autogenous bone graft particles could act as early new bone growth mediators and promote earlier healing. This could result in increased initial torque values, higher implant stability quotient values, decreased micromotion, and more predictable progression to secondary stability. The possibility of achieving immediate or early loading parameters is enhanced.

DISCLOSURE

No funding was received for this work. Drs. F. B. Slete and P. Olin both have a minority financial interest in Versah, LLC.

APPROVAL

This study did not involve live or *in vivo* use of human or animals and did not require IRB or ERB approval.

REFERENCES

1. Abraham CM. Suppl 1: A brief historical perspective on dental implants, their surface coatings and treatments. *Open Dent J*. 2014;8:50–55.
2. O'Sullivan D, Sennerby L, Meredith N. Measurements comparing the initial stability of five designs of dental implants: A human cadaver study. *Clin Impl Dent Relat Res*. 2000;2:85–92.
3. Akca K, Chang TL, Tedemir I. Biomechanical aspects of initial intraosseous stability and implant design: A quantitative micro-morphometric analysis. *Clin Oral Impl Res*. 2006;17:465–472.
4. Natali C, Ingle P, Dowell J. Orthopaedic bone drills—can they be improved? Temperature changes near the drilling face. *J Bone Joint Surg Br*. 1996;78:357–362.
5. Yoon HG, Heo SJ, Koak JY, et al. Effect of bone quality and implant surgical technique on implant stability quotient (ISQ) value. *J Adv Prosthodontol*. 2011;3:10–15.
6. Meredith N. Assessment of implant stability as a prognostic determinant. *Int J Prosthodontol*. 1998;11:491–501.

7. Javed F, Romanos GE. The role of primary stability for successful immediate loading of dental implants. A literature review. *J Dent*. 2010;38:612–620.
8. Pagliani L, Sennerby L, Peterson A, et al. The relationship between resonance frequency analysis (RFA) and lateral displacement of dental implants: An in vitro study. *J Oral Rehab*. 2013;40:221–227.
9. Frost HM. A brief review for orthopedic surgeons: Fatigue damage (microdamage) in bone (its determinants and clinical implications). *J Ortho Sci*. 1998;3:272–281.
10. Trisi P, Perfetto G, Baldwin E, et al. Implant micromotion is related to peak insertion torque and bone density. *Clin Oral Impl Res*. 2009;20:467–471.
11. Jackson CJ, Ghosh SK, Johnson W. On the evolution of drill-bit shapes. *J Mechan Work Tech*. 1989;18:231–267.
12. Bertollo N, Walsh WR. Drilling of bone: Practicality, limitations and complications associated with surgical drill-bits. In: Kilka V, ed. *Biomechanics in Applications*. Rijeka, Croatia: INTECH; 2011:53–58.
13. Summers RB. A new concept in maxillary implant surgery: The osteotome technique. *Compendium*. 1994;15:152–154.
14. Green JR, Memzek JA, Amoczky SP, et al. The effect of bone compaction on early fixation of porous-coated implants. *J Arthro*. 1999;14:91–97.
15. Kold S, Rahbek O, Vestermark M, et al. Bone compaction enhances fixation of weight-bearing titanium implants. *Clin Ortho Rel Res*. 2005;431:138–144.
16. Kold S, Rahbek O, Vestermark M, et al. Bone compaction enhances fixation of weight-bearing hydroxyapatite-coated implants. *J Arthro*. 2006;21:263–270.
17. Peñarrocha M, Pere H, Garcia A, et al. Benign paroxysmal positional vertigo as a complication of osteotome expansion of the maxillary alveolar ridge. *JOMI*. 2001;59:106–107.
18. Huwais S, Meyer HG. A novel osseous densification approach in implant osteotomy preparation to increase biomechanical primary stability, bone mineral density, and bone-to-implant contact. *JOMI*. 2017;32:27–36.
19. Huwais S, inventor; Fluted osteotome and surgical method for use. US Patent Application US2013/0004918. January 3, 2013.
20. Huwais S. *Autografting Osteotome*. Geneva, Switzerland: World Intellectual Property Organization Publication; May 22, 2014. WO2014/077920.
21. Rohrer MD, Schubert CC. The cutting-grinding technique for histological preparation of undecalcified bone and bone-anchored implants. Improvements in instrumentation and procedures. *Oral Surg Oral Med Oral Pathol*. 1992;74:73–78.
22. Donath K, Breuner G. A method for the study of undecalcified bones and teeth with the attached soft tissues: The sage Schliff (sawing and grinding) technique. *J Oral pathol*. 1982;11:318–326.
23. Schlegel KA, Kloss FR, Kessler P, et al. Bone conditioning to enhance implant osseointegration: An experimental study in pigs. *JOMI*. 2003;18:505–511.
24. Järvinen TL, Sievannen H, Jokihara F, et al. Revival of bone strength: The bottom line. *J Bone Min Res*. 2005;20:717–720.
25. Carter DR, Hayes WC. The compressive behavior of bone as a two-phase porous structure. *J Bone Joint Surg*. 1977;59:954–962.
26. Wirth AJ, Goldhahn J, Flaig C, et al. Implant stability is affected by local bone microstructural quality. *Bone*. 2011;49:473–478.
27. Stavropoulos A, Nyengaard JR, Lang NP, et al. Immediate loading of single SLA implants: Drilling vs. osteotomes for the preparation of the implant site. *Clin Oral Impl Res*. 2008;19:55–65.
28. Büchter A, Lieinheinz J, Wiesmann HP, et al. Biological and biomechanical evaluation of bone remodelling and implant stability after using an osteotome technique. *Clin Oral Impl Res*. 2005;16:1–8.
29. Rossi F, Lang NP, Santis E, et al. Bone-healing pattern at the surface of titanium implants: An experimental study in the dog. *Clin Oral Impl Res*. 2014;25:124–131.
30. Tabassum A, Walboomers XF, Meijer GJ, et al. Translocation of autogenous bone particles to improve peri-implant osteogenesis. *J Tis Eng Reg Med*. 2012;6:519–527.
31. Lopez CD, Alifrag AM, Torroni A, et al. Osseodensification for enhancement of spinal surgical hardware fixation. *J Mech Behav Biomed Mat*. 2017;69:275–281.