

# Osseodensified Crestal Sinus Window Augmentation: An Alternative Procedure to the Lateral Window Technique

Nilesh Salgar, DDS

A novel minimally invasive technique, osseodensification, is proposed to facilitate maxillary sinus bone graft augmentation. The osseodensified crestal window overcomes the previous limitations of traditional crestal approaches with respect to residual bone height (RBH) of  $\leq 1.5$  mm as well as vertical height of augmentation ( $>10$  mm). Three patients, healthy and non-smoking, with 3 distinct and difficult clinical situations requiring sinus augmentation and having a maximum of 1.5 mm RBH (0.4–1.5 mm) were selected for this procedure. Edentulous sections were large (entire posterior sextant, with and without sinus septa), and small (single hyperpneumatized maxillary molar site). All healing was rapid and uneventful with no instances of sinus membrane perforation or other complications seen. The vertical increase in sinus bone height ranged from 10.3 mm to 13.6 mm. The increase in bone height is comparable to that obtained with lateral window procedures. The osseodensified crestal sinus window technique may be thus be proposed as a possible alternative procedure for the lateral sinus window technique for maxillary sinus bone augmentation.

**Key Words:** dental implant, sinus graft, osseodensification, transcrestal, residual bone height, lateral window

## INTRODUCTION

When assessing a potential future implant site, if the implant does not “fit” due to a deficiency of hard or soft tissue, then the clinician and patient must commit to a bone, tissue, or sinus graft to augment that site. The posterior maxilla poses several challenges for the placement of dental implants. Bone and tissue loss from periodontal disease, post-extraction bone atrophy in height and width, pneumatization of the maxillary sinuses, poor bone density, and very high occlusal forces are some factors leading to this difficulty. Bone grafting in the maxillary sinus is the solution to obtain adequate bone volume for implant placement.

High-resolution 3D cone-beam computed tomography (CBCT) is the gold standard for imaging and treatment planning dental implants in the maxillary sinus. Multiple factors such as residual bone height (RBH), presence of teeth, size and shape of the sinus, septa, and pathology, must be assessed.

The lateral sinus window technique has been the traditional method of choice to augment the sinus in patients presenting with a severely resorbed and atrophied posterior maxilla. The lateral window is the procedure of choice in cases presenting with a larger edentulous region of several teeth, a significant volume of bone grafting required, and a RBH  $< 5$  mm. Implant placement is usually delayed in these cases where the RBH is less than 5 mm.<sup>1</sup> Several of the main disadvantages of the lateral window are the need to raise a large flap, Schneiderian membrane perforation, presence of septa, difficulty in design and preparation of the bony window, thick bony lateral wall, and injury to blood vessels found in the lateral bony wall.

The maxillary sinus septum is an anatomical irregularity that poses a serious complication to the lateral sinus window procedure. The vast majority of septa, 87.6%, are transverse, or buccopalatal in orientation.<sup>1</sup> 3D CBCT diagnostic imaging must be done to evaluate the location, size, and orientation of the sinus and its septa. It is often necessary to modify the size and shape of the lateral window to compensate for the presence of the septum. Several of the strategies are as follows. If the septum is high, 2 windows, one posterior and the other anterior to the septum may be made. If the septum is low, a modified “W” shaped window may be created.<sup>1,2</sup> In either septum situation, the risk of perforating the Schneiderian membrane is very high and the buccal window of bone should not be inverted (trapdoor technique)<sup>3</sup> in the presence of the septum.

For the last 35 years, the main surgical approaches have been described by Tatum,<sup>4</sup> and Summers.<sup>5,6</sup> Several modified techniques have also been described: osteotomes,<sup>7</sup> balloon,<sup>8</sup> reamers,<sup>9</sup> hydraulic pressure,<sup>10</sup> and piezosurgery.<sup>11</sup>

The crestal sinus approach is indicated when there is at least 5 mm remaining crestal bone height, and primary implant stability can usually be achieved.<sup>12,13</sup> The crestal approach is generally considered to be a far less invasive procedure with less complications, less postoperative pain, and less swelling for patients. One main disadvantage of the transcrestal approach is that the procedure is relatively blind and there is the possibility of perforating the Schneiderian membrane due to reduced visibility, and not knowing that such a perforation has occurred. Although the transcrestal approach is a blind procedure, the frequency of Schneiderian membrane perforation is reported as less than the lateral approach.<sup>14,15</sup> Perforation of the Schneiderian membrane would lead to loss of the graft material into the sinus, and failure of the procedure. There is a very limited ability to repair a membrane perforation through the crestal approach compared to the lateral window procedure.

Traditional crestal sinus augmentation techniques, howev-

Private practice, Kirkland, Quebec, Canada.

\* Corresponding author, e-mail: drnileshsalgar@hotmail.com  
<https://doi.org/10.1563/aaid-joi-D-19-00288>

er, have been unable to accomplish the amount of vertical bone gain obtained by the lateral sinus window procedure. Several studies: Zitmann and Scharer,<sup>13</sup> Woo and Le,<sup>14</sup> and Pal and colleagues<sup>16</sup> have found a statistically significant difference in the bone gain height between crestal and lateral techniques with a typical mean gain of only 3 to 4 mm for the crestal approach.<sup>13</sup>

The author is proposing a novel transcrestal window sinus lift technique (osseodensification) that bypasses the long-established restrictions and disadvantages of transalveolar crestal augmentation. The proposed crestal technique is a potentially safe and effective procedure that produces an increase in bone height comparable to that obtained with traditional lateral window procedures. This innovative technique may provide a viable alternative to the rationale for the lateral window approach.

Osseodensifying burs are used to densify alveolar bone by rotating in the noncutting counterclockwise (CCW) direction at 800–1200 RPM.<sup>17</sup> Copious amounts of irrigation fluid induce a pressure wave ahead of the bur. This facilitates the autografting of bone particles along the inner surface walls and apex of the osteotomy. This autografting also serves to densify the inner walls of the osteotomy.<sup>17</sup> The sinus floor can thus be penetrated by the CCW nonexcavating bur. The slurry of irrigation fluid and autogenous bone chips creates the gentle hydraulic detachment and elevation of the Schneiderian membrane.<sup>18</sup> The sinus is therefore augmented with a potentially low risk of perforation.

This paper presents 3 distinct and difficult clinical situations requiring maxillary sinus augmentation indicated for this procedure having a RBH < 1.5 mm:

- Clinical situation 1: edentulous posterior maxilla with large pneumatized maxillary sinus.
- Clinical situation 2: edentulous posterior maxilla with large pneumatized maxillary sinus complicated by transverse septum compartmentalization.
- Clinical situation 3: single missing posterior tooth with severely pneumatized sinus and adjacent roots forming the mesial and distal sinus walls (with a very large and radiographically visible blood vessel present in the lateral wall of the sinus).

### Case reports

*Description of technique and surgical procedure (common to each case)*

Three patients, healthy and non-smoking, with 3 distinct and difficult clinical situations requiring sinus augmentation and having a maximum of 1.5 mm RBH (0.4–1.5 mm) were selected for this procedure. Edentulous sections were large (entire posterior sextant, with and without sinus septa) and small (single hyperpneumatized maxillary molar site).

The author ensured compliance with EQUATOR Guidelines (CARE Case Report Checklist).

Preoperative radiographs (Figures 2a, 6a, and 8a) and 3D CBCT imaging (Figures 1, 5, and 9) were performed to determine bone volume and rule out sinus pathology prior to surgery. Postoperative radiographs (Figures 2b, 6b, and 8b) and

CBCT (Figure 4) were used to measure the amount and height of bone augmentation in the sinus.

Informed consent was thoroughly read and explained to the patients and all questions answered 1 week prior to the procedure. Prophylactic antibiotics (amoxicillin, 500 mg, three times a day [tid] for 1 week) was started 1 day prior with an additional dose of 2 g taken 1 hour before the procedure. The patient was to rinse with chlorhexidine, 0.12%, preoperation and tid for 2 weeks post-operation. ibuprofen, 600 mg, every 4 to 6 hours, was prescribed as analgesic.

Preoperative 3-D CBCT imaging was done. The CBCT was converted to a 3D file (Simplant; Dentsply Sirona, York, Penn) to allow multiple views, rotation and familiarization of the 3D image. An assessment was done of the size, shape, and volume of the maxillary sinus and the bone height needed for the future dental implant procedure. A thorough evaluation of the sinus anatomy and septa was done. There was no sinus pathology present prior to the surgical procedures. Measurement of the sinus floor RBH (0.4–1.5 mm) was measured with CBCT and digital periapical radiographs (Dexis; KaVo Dental, Danaher Corp, Washington DC).

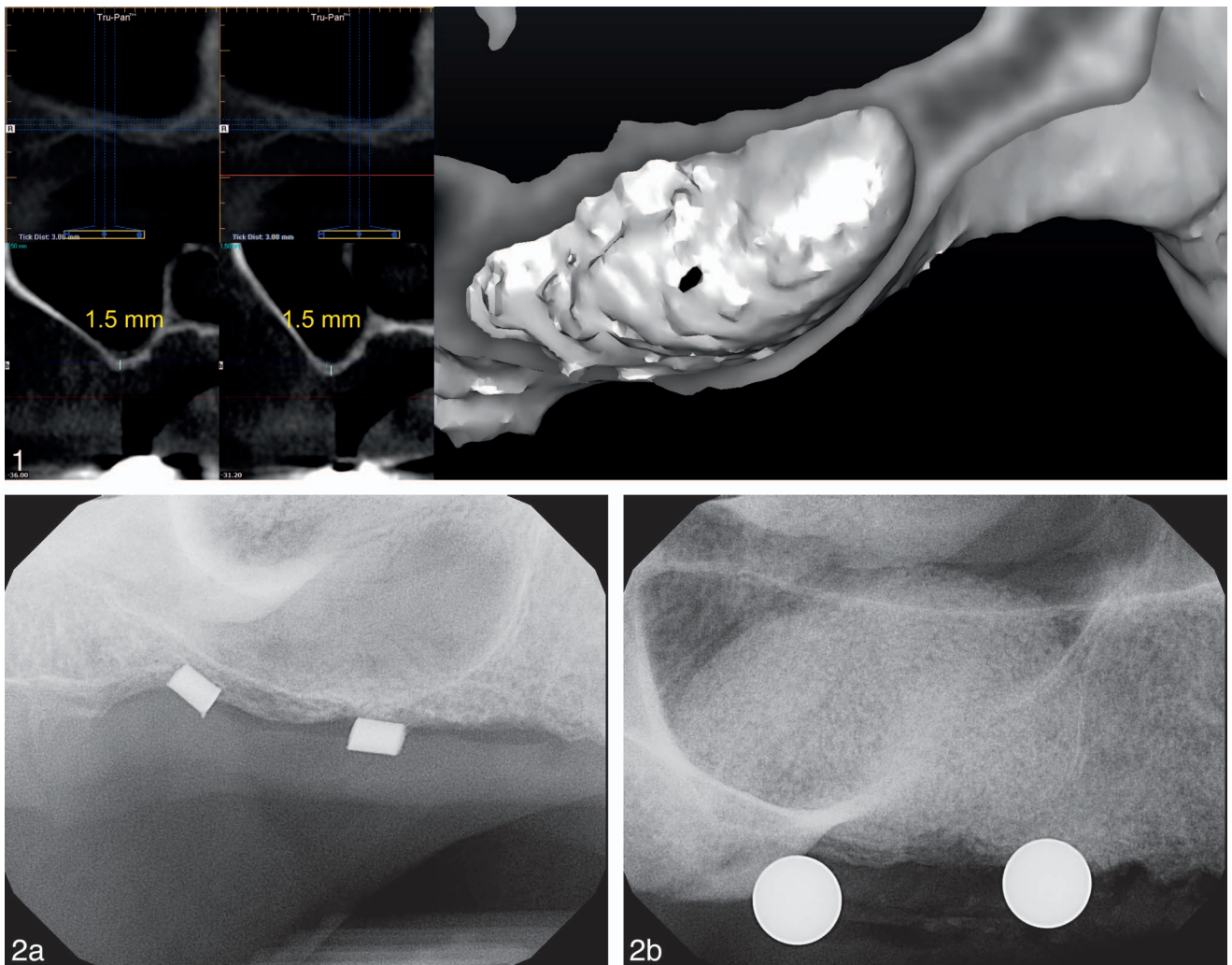
The posterior quadrant was anaesthetized with 2 carpules of lidocaine 2% (1:50 000) (xylocaine; Dentsply) via buccal and palatal infiltration. A full-thickness flap was elevated with a periosteal releasing incision.

For clinical situations 1 and 2, 2 osteotomy sites were planned, one in the posterior, the other in the anterior region of the sinus (and septum). Confirmation of the osteotomy positions was done with two gutta percha markers (Figures 3a and 7a) and digital periapical radiographs (Figures 2a and 6a).

For clinical situation 3, the osteotomy was made in the center of the alveolar crest of the missing first maxillary molar (Figure 10a).

Purchase points (a groove or notch on the bone surface) were made on the crest of the ridge at the confirmed osteotomy positions with a high-speed large round diamond bur and copious irrigation. A 3.0-mm diameter Densah bur (Versah, LLC, Jackson, Miss) in osseodensification mode (CCW drill speed 1100 RPM with copious irrigation) and gentle pressure was used to reach and penetrate the floor of the sinus (Figures 3b, 7b). The sinus membrane was visible and intact. Using modulating pressure with a pumping motion, this bur was advanced past the sinus floor in 1-mm increments, up to a maximum of 3 mm. Maximum bur advancement past the sinus floor, at any stage, must not exceed 3 mm. The osteotomy diameter was increased with the next successive Densah burs 4.0 mm (Figure 10b), 5.0 (Figures 3c and 7d), and 5.3 mm (Figure 10d) in osseodensification Mode (CCW 1100 RPM with copious irrigation) to achieve sinus membrane lift of 3 mm in 1-mm increments. Again, the sinus membrane was visible and intact.

The osteotomy sites were filled with well hydrated mineralized cortical allograft (MTF Symbios; Dentsply Sirona) (Figures 3d, 7e and 10e). The final Densah bur 5.0 mm (Figures 3e and f, 7f), or 5.3 mm (Figures 10f) was used in osseodensification mode (CCW) at low speed (150 RPM) and no irrigation to gently propel the allograft into the sinus. The Densah Bur only facilitates the allograft material compaction to



**FIGURES 1 AND 2. FIGURE 1.** Clinical situation 1: edentulous posterior maxilla with large maxillary sinus. (a) Cone beam computerized tomography (CBCT) image; posterior crestal sinus osteotomy site; residual bone height (RBH) = 1.5 mm. (b) CBCT image; anterior crestal sinus osteotomy site; RBH = 1.5 mm. (c) Simplant 3D image of maxillary sinus interior anatomy. **FIGURE 2.** (a) Digital radiograph of gutta percha markers confirming osteotomy positions. (b) Postoperative radiographs showing final crestal sinus bone augmentation. A clearly defined, dome shaped augmentation of bone is seen on the radiograph, confirming the intact Schneiderian membrane and full containment of the graft volume. Final elevated sinus height: 12 mm (posterior site) and 15 mm (anterior site).

further lift the sinus membrane. The bur was not advanced more than 3 mm beyond the sinus floor. The graft propelling step was repeated 10 to 15 more times to facilitate additional membrane lift. Each successive grafting step produces a vertical sinus augmentation of approximately 1 mm. This step would be repeated by the surgeon as needed according to the future planned implant length. 3.0 mL of allograft was used in clinical situations 1 and 2. In clinical situation 3, 1.0 mL of allograft was used.

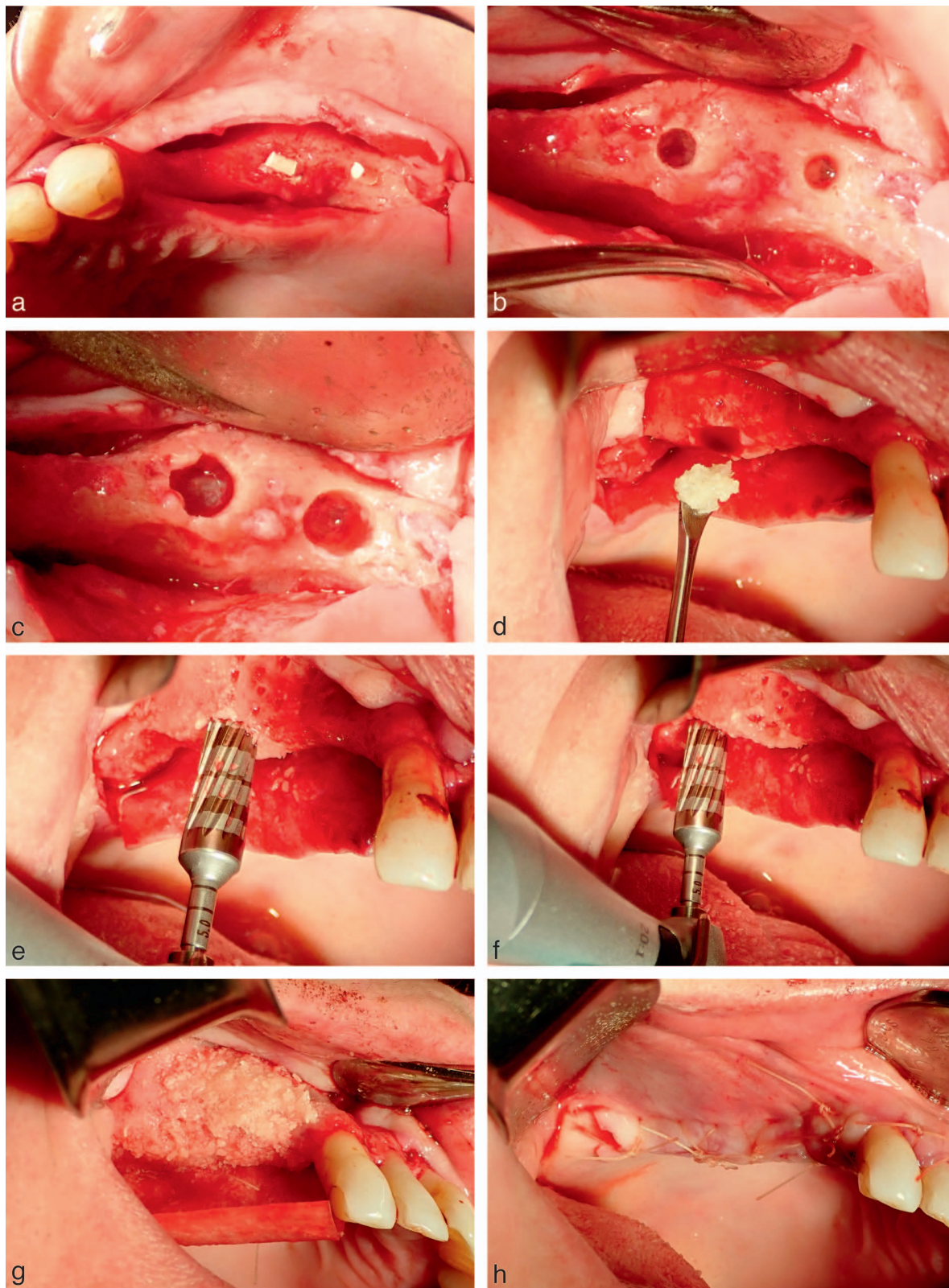
#### *Adjunct ridge augmentation grafting procedure*

For clinical situation 1 and 2: Horizontal ridge augmentation was also performed concomitantly in the premolar region of the quadrant. Bleeding points were created in the buccal cortical plate of the ridge in the premolar region with a high-speed #330 bur and copious irrigation. A long-lasting (26–38 weeks) collagen membrane (MTF Symbios OsteoShield; Dents-

ply Sirona) was custom cut to extend over the ridge to protect the allograft on the buccal and palatal (Figures 3g and 7g). The membrane was sutured to the lingual flap with 3:0 polyglycolic acid (PGA) sutures (Polysyn; Look, Surgical Specialties Corp, Westwood, Mass). Mineralized cortical allograft bone (MTF Symbios) was used to augment the ridge concavities and defects over the buccal cortical plate. The membrane was then draped over the bone graft and over the buccal plate.

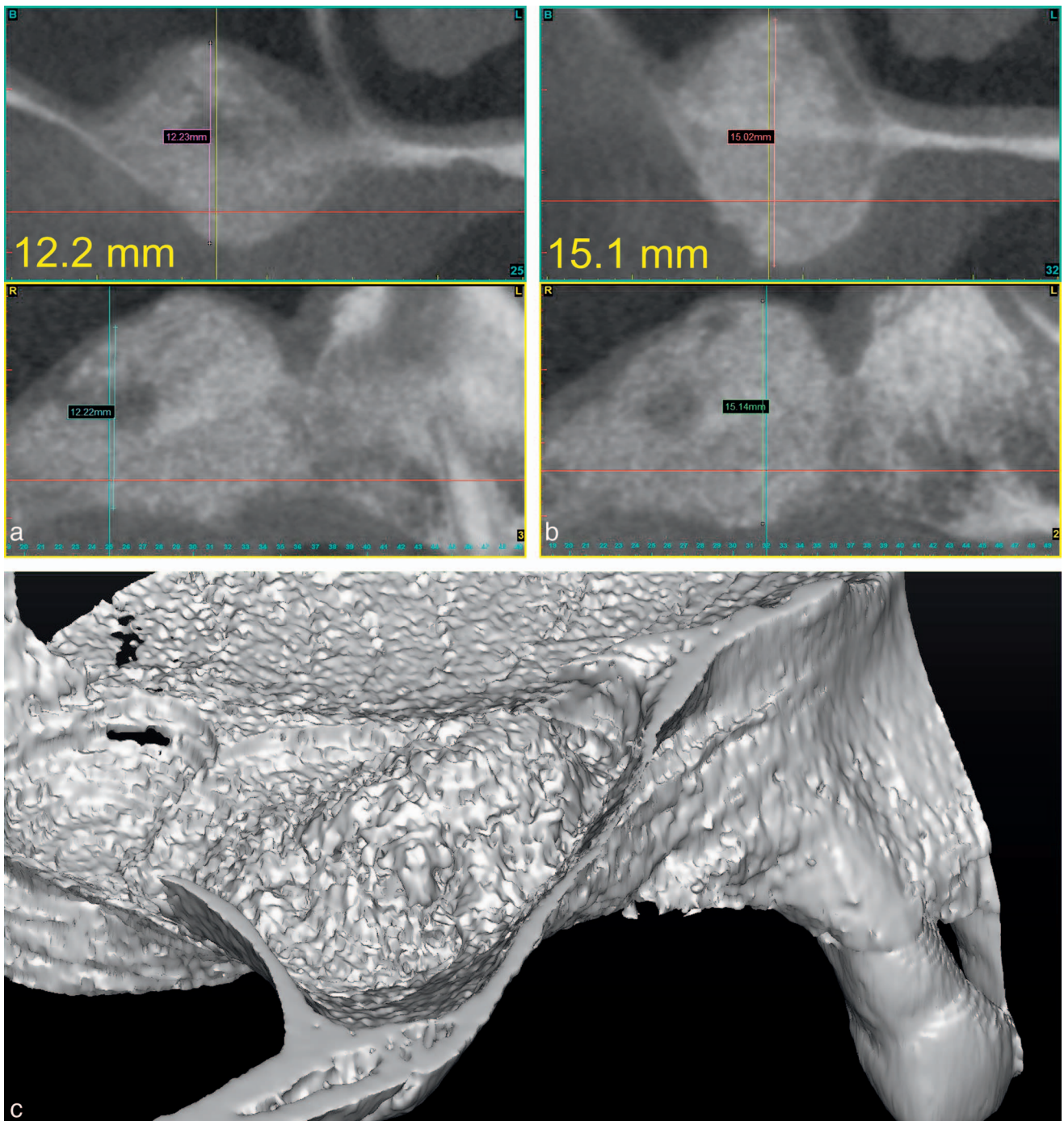
The flaps were then repositioned over the bone and membrane (Figures 3g, 7g, and 10g). Tension-free primary closure was achieved with 3:0 polyglycolic acid sutures (PolySyn; Look) (Figures 3h, 7h, and 10h). Postoperative follow-up digital radiographs (Figures 2b, 6b, and 8b) were taken to measure the vertical increase in bone height of the sinus augmentation. A vertical increase of 10.3 to 13.6 mm was seen in the sinus. A clearly defined, dome-shaped augmentation of bone is seen on the radiographs, confirming the intact





**FIGURE 3.** Clinical situation 1: edentulous posterior maxilla with large maxillary sinus. (a) Confirmation of the osteotomy positions with 2 gutta percha markers and digital radiograph.(b) Two 3.0-mm osteotomy sites (anterior and posterior positions) through sinus floor with Densah bur Ø 3.0. Note intact sinus membrane. (c) Two 5.0-mm osteotomy sites (anterior and posterior positions) through sinus floor with Densah bur Ø 5.0. Note intact sinus membrane. (d) Osteotomy site filled with hydrated mineralized cortical allograft. (e) Densah Bur Ø 5.0 used in osseodensification mode (counterclockwise) at low speed (150 RPM) and no irrigation to gently propel the allograft into the sinus-





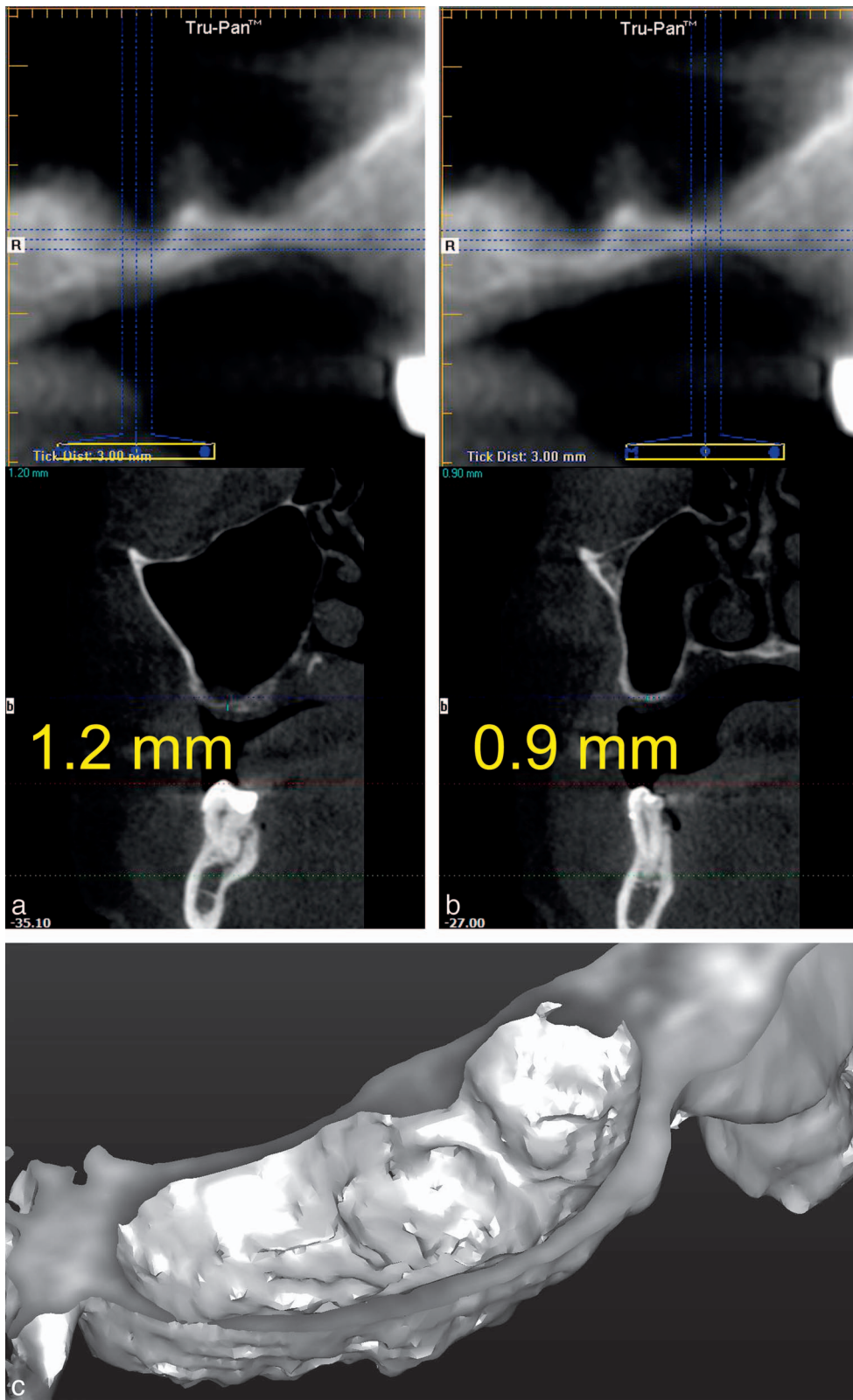
**FIGURE 4.** Clinical situation 1: edentulous posterior maxilla with large maxillary sinus. (a) Cone beam computerized tomography (CBCT) image; posterior crestal osteotomy site; sinus bone height = 12.2 mm. (b) CBCT image; anterior crestal osteotomy site; sinus bone height = 15.1 mm. (c) Simplant 3D image of maxillary sinus interior anatomy. Note the clearly defined, dome-shaped augmentation of bone in the sinus.

Schneiderian membrane with no perforation and full containment of the graft volume under the membrane.

Excellent rapid and uneventful healing was observed. All 3 patients reported minimal postoperative discomfort and

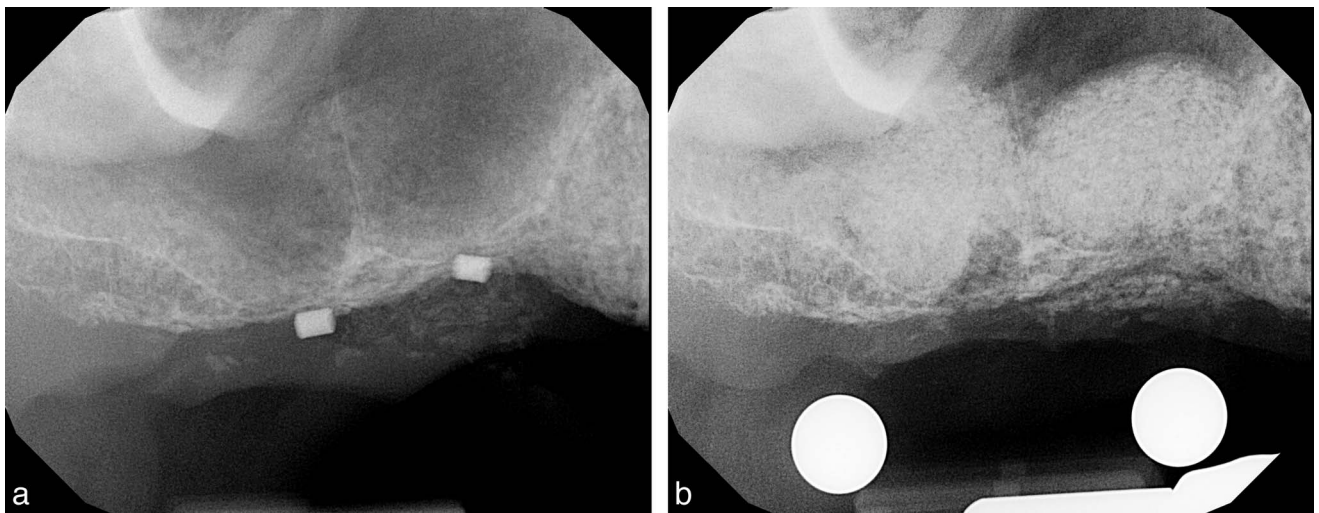
bleeding with no swelling. There was no incidence of sinus Schneiderian sinus membrane perforation or other surgical complications seen. The sutures were removed after 12 days. Follow-up visits were at 1, 2, and 4 months.

← anterior osteotomy site. (f) Densah Bur Ø 5.0 used to propel the allograft into sinus-posterior osteotomy site. (g) Adjunct ridge augmentation graft procedure using mineralized cortical allograft and long-lasting collagen membrane. (h) Primary closure: tension-free 3:0 PGA sutures.



**FIGURE 5.** Clinical situation 2: edentulous posterior maxilla with large maxillary sinus and transverse septum compartmentalization. (a) Cone beam computerized tomography (CBCT) image; posterior crestal sinus osteotomy site: RBH = 1.2 mm. (b) CBCT image; anterior crestal sinus osteotomy site: RBH = 0.9 mm. (c) Simplant 3D image of maxillary sinus interior anatomy. Note the presence of the transverse septum on the floor of the sinus.





**FIGURE 6.** Clinical situation 2: edentulous posterior maxilla with large maxillary sinus and transverse septum compartmentalization. (a) Digital radiograph of gutta percha markers confirming osteotomy positions. (b) Postoperative radiographs showing final crestal sinus bone augmentation. Two clearly defined, dome-shaped augmentations of bone are seen on the radiographs, confirming the intact Schneiderian membrane and full containment of the graft volume. Final elevated sinus height: 13.0 mm (posterior site) and 11.2 mm (anterior site).

### RESULTS

For Table 1, the mean ages of the patients were  $54.3 \pm 6.2$  years (range: 46–61 years).

The mean initial (pre-op), final (post-op), and sinus membrane vertical bone gain was:

$1.1 \pm 0.4$  mm,  $13.0 \pm 1.3$  mm, and  $11.9 \pm 1.3$  mm.

### DISCUSSION

Traditionally the lateral window approach with delayed implant placement has been recognized as the surgical technique of choice in cases where the RBH is less than 5 mm due to the lack of implant primary stability in such situations.<sup>13</sup>

Other authors have reported cases with transcrestal Schneiderian membrane elevations of 3.8 to 12 mm,<sup>7,19,20</sup> using either osteotomes, hydraulic detachment, or piezosurgery.

To the author's knowledge, no other investigators have demonstrated the use of this single simplified surgical technique (osseodensification) for the crestal approach to maxillary sinus augmentation with a residual bone height of  $\leq 1.5$  mm (0.4–1.5 mm) to achieve a vertical height of sinus augmentation of  $>10$  mm (10.3–13.6 mm). The increase in bone height is comparable to that obtained with lateral window procedures.

To the author's knowledge, no investigators have demonstrated the use of one technique (osseodensification) for the 3 distinct and difficult clinical situations indicated for maxillary sinus augmentation when the RBH is  $<1.5$  mm:

1. Edentulous posterior maxilla with large maxillary sinus.
2. Edentulous posterior maxilla with large maxillary sinus complicated by transverse septum compartmentalization.
3. Single missing posterior tooth with severely pneumatized sinus and adjacent roots forming the mesial and distal sinus walls.

The osseodensified crestal sinus window technique may be proposed as a possible alternative procedure for the lateral sinus window technique for maxillary sinus bone augmentation.

It should be noted that the safety and effectiveness of this procedure depends on cautious planning as well as the skill and advanced training of the surgeon. The inexperienced or novice surgeon may have a higher likelihood to develop or induce a perforation of the sinus membrane. For this reason the author strongly advises a thorough familiarization and proficient experience with the lateral sinus window surgical technique.

Despite the limitations of this study: the small number of cases (3) and short follow-up (1 year), based on the results obtained, it may be suggested that the described technique may represent a viable alternative procedure in maxillary sinus augmentation via the crestal approach.

Further studies will be required to determine its statistical effectiveness in relation to the vertical gain success rate of the traditional lateral sinus window procedure.

These clinical case studies do, however, demonstrate the potential ability of this novel osseodensification crestal window approach to augment the maxillary sinus for standard length implant placement ( $\geq 9$  mm implant length) in the hyperpneumatized posterior maxilla with a RBH  $< 1.5$  mm. Placement of dental implants would be staged or delayed in such situations due to a lack of primary stability from the extremely thin RBH used for any such anchorage.

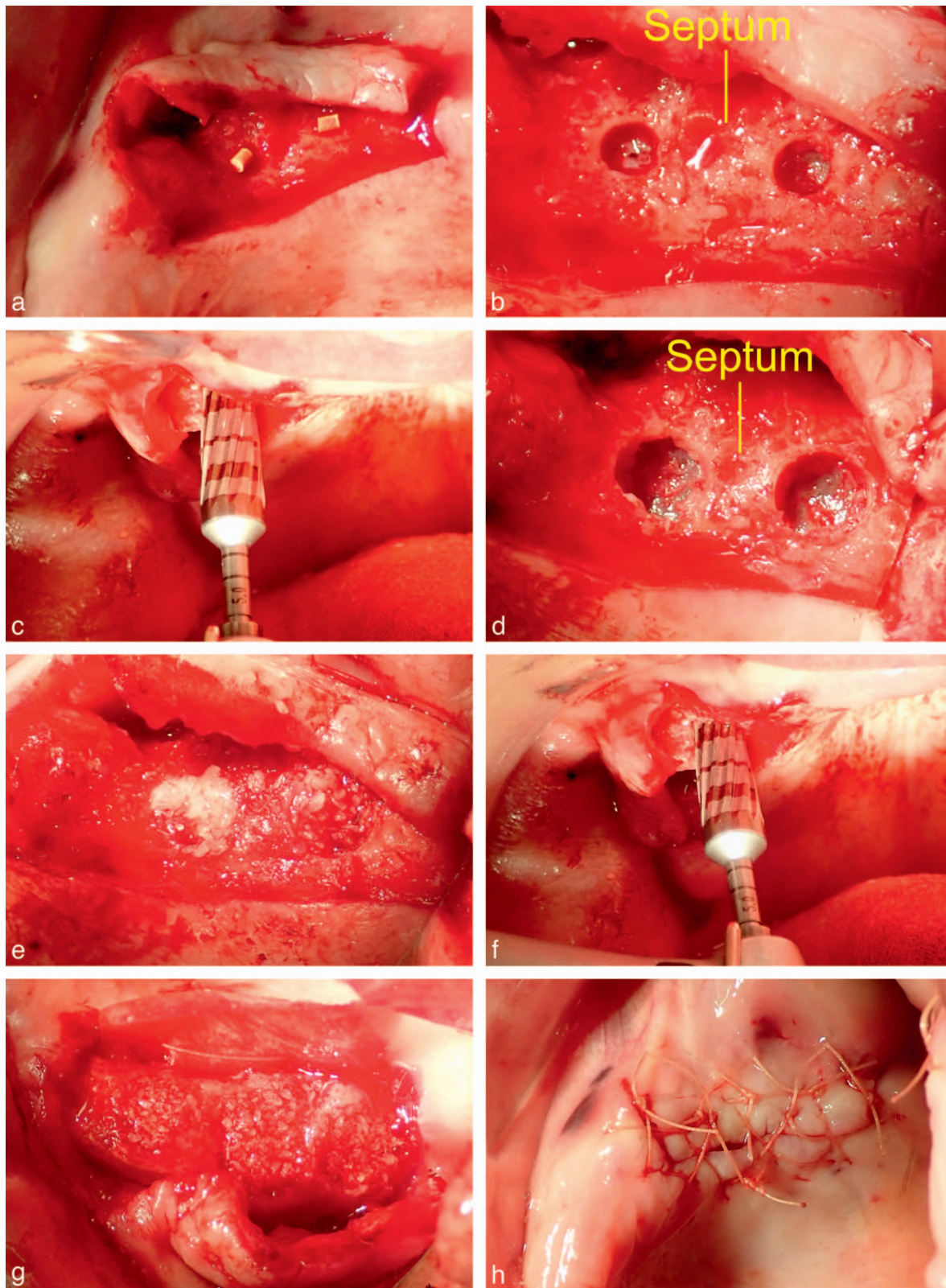
### ABBREVIATIONS

CBCT: cone beam computerized tomography

CCW: counterclockwise

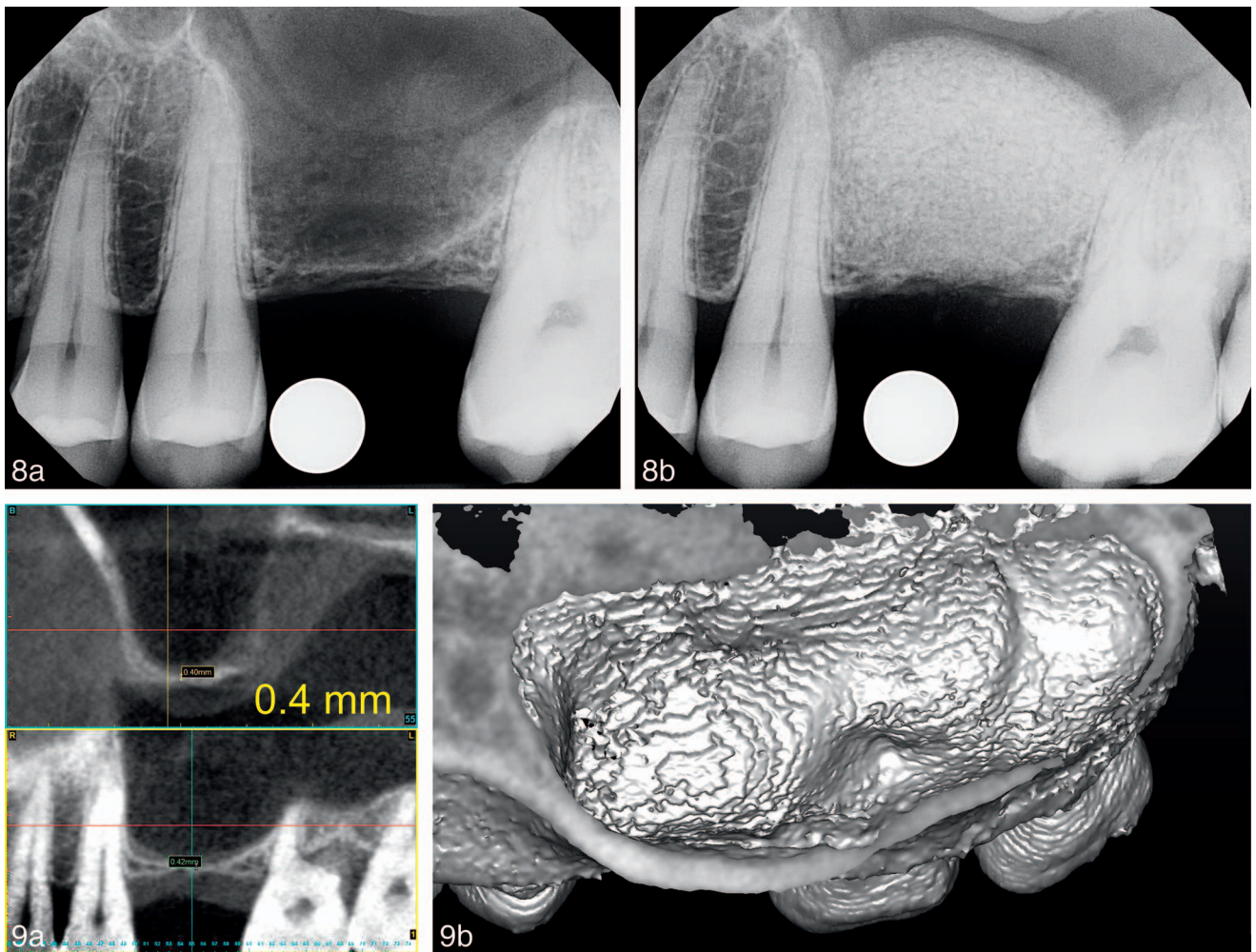
RBH: residual bone height

tid: 3 times a day



**FIGURE 7.** Clinical situation 2: edentulous posterior maxilla with large maxillary sinus and transverse septum compartmentalization. (a) Confirmation of the osteotomy positions (anterior and posterior to the transverse septum) with two gutta percha markers and digital radiograph. (b) Two 3.0-mm osteotomy sites through sinus floor made with Densah bur Ø 3.0. Note intact sinus membrane. (c) Densah bur Ø 5.0 used in osseodensification mode (counterclockwise [CCW]) at 1100 RPM and copious irrigation to advance past the sinus floor in 1 mm increments up to a maximum of 3 mm. (d) Two 5.0-mm osteotomy sites (anterior and posterior positions) through sinus floor with





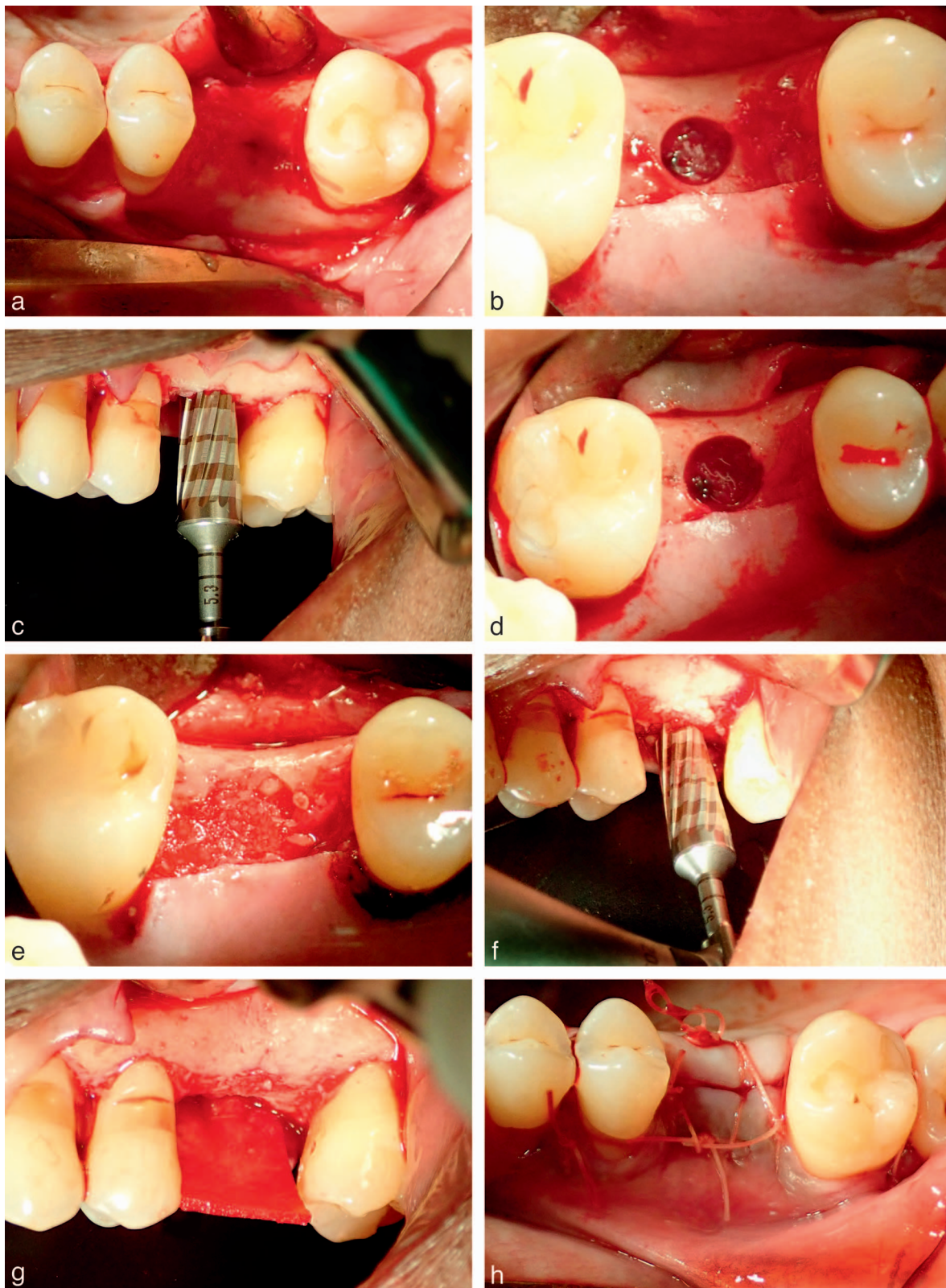
**FIGURES 8 AND 9.** **FIGURE 8.** Clinical situation 3: single missing posterior tooth with severely pneumatized sinus and adjacent roots forming the mesial and distal sinus walls. (a) Digital radiograph of initial RBH = 0.4 mm. Note the intraosseous artery in lateral bony wall of sinus—a significant complication for the lateral window technique. (b) Digital radiograph post-op; verification of intact Schneiderian membrane fully containing allograft graft volume. Final elevated sinus height: 13.5 mm (13.1-mm vertical augmentation). Note the intraosseous artery in lateral bony wall of sinus. **FIGURE 9.** (a) Cone beam computerized tomography (CBCT) image; posterior crestal sinus osteotomy site: RBH = 0.4 mm. (b) CBCT image; anterior crestal sinus osteotomy site: RBH = 0.4 mm. (c) Simplant 3D image of maxillary sinus interior anatomy.

	Patient 1		Patient 2		Patient 3	Mean and SD
Age (y)	61		46		56	54.3 ± 6.2
Sinus location	Posterior	Anterior	Posterior	Anterior	Mid-Crestal	
Pre-op RBH (mm)	1.5	1.5	1.2	0.9	0.4	1.1 ± 0.4
Post-op height (mm)	12.2	15.1	13.0	11.2	13.5	13.0 ± 1.3
Vertical gain (mm)	10.7	13.6	11.8	10.3	13.1	11.9 ± 1.3

\*RBH indicates residual bone height; SD, standard deviation.

Densah bur Ø 5.0. Note intact sinus membrane. (e) Osteotomy site filled with hydrated mineralized cortical allograft. (f) Densah bur Ø 5.0 used in osseodensification mode (CCW) at low speed (150 RPM) and no irrigation to gently propel the allograft into the sinus up to a maximum of 3 mm past the sinus floor—anterior osteotomy site. (g) Adjunct ridge augmentation graft procedure using mineralized cortical allograft and long-lasting collagen membrane. (h) Primary closure: tension-free 3:0 PGA sutures.





**FIGURE 10.** Clinical situation 3: single missing posterior tooth with severely pneumatized sinus and adjacent roots forming the mesial and distal sinus walls. (a) Full-thickness flap. Crestal osteotomy position at the center of the alveolar crest of the missing first maxillary molar. (b) 4.0-mm osteotomy site through sinus floor made with Densah bur  $\varnothing$  4.0. Note intact sinus membrane. (c) Densah Bur  $\varnothing$  5.3 used in osseodensification mode (counterclockwise [CCW]) at 1100 RPM and copious irrigation to advance past the sinus floor in 1-mm increments up to a maximum of 3 mm past the sinus floor. (d) 5.3-mm osteotomy site through sinus floor with Densah bur  $\varnothing$  5.3. Note intact sinus



## ACKNOWLEDGMENTS

The author has no conflict of interest nor financial interest, either directly or indirectly, in the products or information listed in the article.

## REFERENCES

1. Fugazotto PA. Augmentation of the posterior maxilla: a proposed hierarchy of treatment selection. *J Periodontol.* 2003;74:1682–1691.
2. Betts NJ, Miloro M. Modification of the sinus lift procedure for septa in the maxillary antrum. *J Oral Maxillofac Surg.* 1994;52:332–333.
3. Tourbah B, Maarek H. Complications of maxillary sinus bone augmentation: prevention and management. In: Younes R, Nader N, Khoury, G, eds. *Sinus Grafting Techniques. A Step-by-Step Guide.* Switzerland: Springer; 2015:195–233.
4. Tatum H Jr. Maxillary and sinus implant reconstructions. *Dent Clin North Am.* 1986;30:207–229.
5. Summers RB. A new concept in maxillary implant surgery: the osteotome technique. *Compend.* 1994;15:152, 154–156, 158 passim; quiz 162.
6. Summers RB. The osteotome technique: part 3—Less invasive methods of elevating the sinus floor. *Compend.* 1994;15:698, 700, 702–704 passim; quiz 710.
7. Toffler M. Osteotome-mediated sinus floor elevation: a clinical report. *Int J Oral Maxillofac Implants.* 2004;19:266–273.
8. Mazor Z, Kfir E, Lorean A, et al. Flapless approach to maxillary sinus augmentation using minimally invasive antral membrane balloon elevation. *Implant Dent.* 2011;20:434–438.
9. Ahn SH, Park EJ, Kim ES. Reamer-mediated transalveolar sinus floor elevation without osteotome and simultaneous implant placement in the maxillary molar area: clinical outcomes of 391 implants in 380 patients. *Clin Oral Implants Res.* 2012;23:866–872.
10. Kim JM, Sohn DS, Heo JU, et al. Minimally invasive sinus augmentation using ultrasonic piezoelectric vibration and hydraulic pressure: a multicenter retrospective study. *Implant Dent.* 2012;21:536–542.
11. Poblete-Michel M, Michel J-M. *Clinical Success in Bone Surgery Using Ultrasonic Devices.* France: Quintessence Books; 2009.
12. Kim SM, Park JW, Suh JY, et al. Bone-added osteotome technique versus lateral approach for sinus floor elevation: a comparative radiographic study. *Implant Dent.* 2011;20:465–470.
13. Zitzmann NU, Scharer P. Sinus elevation procedures in the resorbed posterior maxilla. Comparison of the crestal and lateral approaches. *Oral Surg Oral Med Oral Pathol Oral Radiol Endo.* 1998;85:8–17.
14. Woo I, Le BT. Maxillary sinus floor elevation: review of anatomy and two techniques. *Implant Dent.* 2004;13:28–32.
15. Taschieri S, Corbella S, Saita M, Tsesis I, del Fabbro M. Osteotome-mediated sinus lift without grafting material: a review of literature and a technique proposal. *Int J Dent.* 2012;2012:9.
16. Pal US, Sharma NK, Singh RK, et al. Direct vs. indirect sinus lift procedure: a comparison. *Natl J Maxillofac Surg.* 2012;3:31–37.
17. Huwais S, Meyer EG. A novel osseous densification approach in implant osteotomy preparation to increase biomechanical primary stability, bone mineral density, and bone-to-implant contact. *Int J Oral Maxillofac Implants.* 2017;32:27–36.
18. Huwais S, Mazor Z, Ioannou AL. A multicenter retrospective clinical study with up-to-5-year follow-up utilizing a method that enhances bone density and allows for transcresal sinus augmentation through compaction grafting. *Int J Oral Maxillofac Implants.* 2018;33:1305–1311.
19. Vitkov L, Gellrich NC, Hannig M. Sinus floor elevation via hydraulic detachment and elevation of the Schneiderian membrane. *Clin Oral Implants Res.* 2005;16:615–621.
20. Wang M, Yan M, Xia H, et al. Sinus elevation through transcresal window approach and delayed implant placement in 1- to 2-mm residual alveolar bone: a case report. *Implant Dent.* 2016;25:866–869.

membrane. (e) Osteotomy site filled with hydrated mineralized cortical allograft. (f) Densah Bur Ø 5.3 used in osseodensification mode (CCW) at low speed (150 RPM) and no irrigation to gently propel the allograft into the sinus up to a maximum of 3 mm past the sinus floor. (g) Osteotomy site filled with mineralized cortical allograft. Long-lasting collagen membrane sutured to palatal flap. (h) Primary closure: tension-free 3:0 PGA sutures.