




RESEARCH ARTICLE

Osseodensification drilling vs conventional manual instrumentation technique for posterior lumbar fixation: Ex-vivo mechanical and histomorphological analysis in an ovine model

Andrea Torroni¹  | Paulo Eduardo Lima Parente² | Lukasz Witek^{3,4}  | Jacques Henri Hacquebord^{5,6}  | Paulo G. Coelho^{1,3,6}

¹Hansjörg Wyss Department of Plastic Surgery, New York University School of Medicine, New York, New York

²Lewis Katz School of Medicine at Temple University, Philadelphia, Pennsylvania

³Department of Biomaterials, New York University College of Dentistry, New York, New York

⁴Department of Biomedical Engineering, New York University Tandon School of Engineering, Brooklyn, New York

⁵Department of Orthopedic Surgery, New York University School of Medicine, New York, New York

⁶Department of Mechanical and Aerospace Engineering, New York University Tandon School of Engineering, Brooklyn, New York

Correspondence

Andrea Torroni, Hansjörg Wyss Department of Plastic Surgery, Bellevue Hospital Center, New York University, 462 1st Ave, Room 5S19A, New York, NY 10010.

Email: andrea.torroni@nyumc.org

Abstract

Lumbar fusion is a procedure associated with several indications, but screw failure remains a major complication, with an incidence ranging 10% to 50%. Several solutions have been proposed, ranging from more efficient screw geometry to enhance bone quality, conversely, drilling instrumentation have not been thoroughly explored. The conventional instrumentation (regular [R]) techniques render the bony spicules excavated impractical, while additive techniques (osseodensification [OD]) compact them against the osteotomy walls and predispose them as nucleating surfaces/sites for new bone. This work presents a case-controlled split model for in vivo/ex vivo comparison of R vs OD osteotomy instrumentation in posterior lumbar fixation in an ovine model to determine feasibility and potential advantages of the OD drilling technique in terms of mechanical and histomorphology outcomes. Eight pedicle screws measuring 4.5 mm × 45 mm were installed in each lumbar spine of eight adult sheep (four per side). The left side underwent R instrumentation, while the right underwent OD drilling. The animals were killed at 6- and 12-week and the vertebrae removed. Pullout strength and non-decalcified histologic analysis were performed. Significant mechanical stability differences were observed between OD and R groups at 6- (387 N vs 292 N) and 12-week (312 N vs 212 N) time points. Morphometric analysis did not detect significant differences in bone area fraction occupancy between R and OD groups, while it is to note that OD showed increased presence of bone spiculae. Mechanical pullout testing demonstrated that OD drilling provided higher degrees of implant anchoring as a function of time, whereas a significant reduction was observed for the R group.

KEYWORDS

biomechanical stability, lumbar spine fixation, manual instrumentation, osseodensification drilling technique, ovine model

1 | INTRODUCTION

Lumbar fusion is a procedure associated with several indications, the most prevalent being spondylolisthesis and scoliosis.¹ Over the past 15 years, the trend of lumbar spine fusion performed in the United States has increased of 62.3%.² Along with the increased volume of lumbar fusion, correlated costs have seen an increase from \$3.7 billion in 2004 to over \$10 billion in 2015 (+177.2%).¹

This escalation of costs has grasped academic attention in order to find suitable ways to limit complications and potential readmissions of patients, a critical factor for the financial sustainability of such procedures.³ Among all complications, one of the most reported is screw loosening and failure, ranging from 10% to 50% as reported in literature.⁴⁻⁶

Integration of screws, and their stability, is the result of two sequential and intimately inter-connected principles: primary, and secondary stability.⁷ Primary stability, the initial mechanical interlocking between implant and bone, depends on the mechanical characteristics of the implant, quality of bone, and instrumentation techniques.⁸ Secondary stability represents the osteointegration of the implant and depends on effective primary stability and the potential of regeneration and remodeling of the bone, favored by physiologic bone metabolism and proper stimulation from the implant through the transmission of appropriate forces.^{7,8} The transition time between primary and secondary stability is variable, commonly taking place between 6 and 8 weeks under favorable conditions.⁸

Several solutions to reduce the incidence of screw failure have been proposed to enhance stability, primarily focusing on screw design, and use of osteosynthesis in combination with various materials.⁹⁻¹³ In contrast, significantly less attention has been focused toward the exploration of alternative instrumentation techniques in an effort to facilitate and improve stability. Recently, a novel non-subtracting drilling technique proved to be effective in improving primary stability of endosteal implants, by creating osseodensification of the drilled bone wall.¹⁴ The design of the drilling burrs is such that the bone is compacted against and into the walls, creating an increased interlock between implant and bone, thus improving levels of primary stability^{7,14} while the viable autogenous grafting sites leading to enhanced osteointegration (Figure 1).^{7,15,16}

This study evaluated instrumentation techniques and their effect the biomechanical stability of lumbar (L) fixation constructs in 8 skeletally mature sheep. With each animal undergoing a L2-L3 and L4-L5 fixation using identical pedicle screws on both sides; the osteotomies on one side were placed following regular manual instrumentation (R), per manufacturer's instructions (Nuvasive, San Diego, CA), while the contralateral side were prepared using the novel osseodensification (OD), drilling instrumentation. Mechanical pull-out test results and histological assessment of bone area fraction occupancy (BAFO) were compared at 6- and 12-week timeline to determine the feasibility and effects of the OD drilling methods on primary and secondary stability.

2 | MATERIALS AND METHODS

2.1 | Animal model and surgical procedure

The study was conducted in accordance with the regulation and disposition of the Institutional Animal Care and Use Committee and included eight skeletally mature female sheep with an age of ~24 months and an average weight of 65 kg.

Anesthesia was induced with sodium pentothal (15-20 mg/kg) in Normasol solution into the jugular vein and maintained with isoflurane (1.5%-3%) in O₂/N₂O (50/50). Animal monitoring included ECG, end tidal CO₂ and SpO₂, and body temperature regulated by a circulating hot water blanket. Prior to surgery, the surgical site was shaved and prepped with iodine solution. Using a #10 blade, a 200 mm vertical incision was performed on the lumbar region of the animal at the midline and deepened through the subcutaneous tissue up to the lumbar fascia; the interspinous and supraspinous ligaments between L2 and L5 were sectioned and the paraspinal muscles were dissected to expose the subperiosteal lamina and roots of the transverse processes of L2 to L5 (Figure 2A). The spinous processes of L2 to L5 were excised and laminectomies were performed bilaterally. To further destabilize the lumbar spine the articular capsule between each facet of L2-L5 was removed to achieve a complete joint derangement. The root of the transverse process was used as reference to place the pedicle screws (Figure 2B); on one side, the insertion protocol consisted of tracing the osteotomy with a pilot hole by a straight gearshift probe, followed by manual instrumentation with a 4.0 mm ($\phi_{\text{actual}} = 3.5$ mm) tapping drill bit



FIGURE 1 Schematic picture of OD drilling method (Image courtesy from Versah LLC). OD, osseodensification [Color figure can be viewed at wileyonlinelibrary.com]

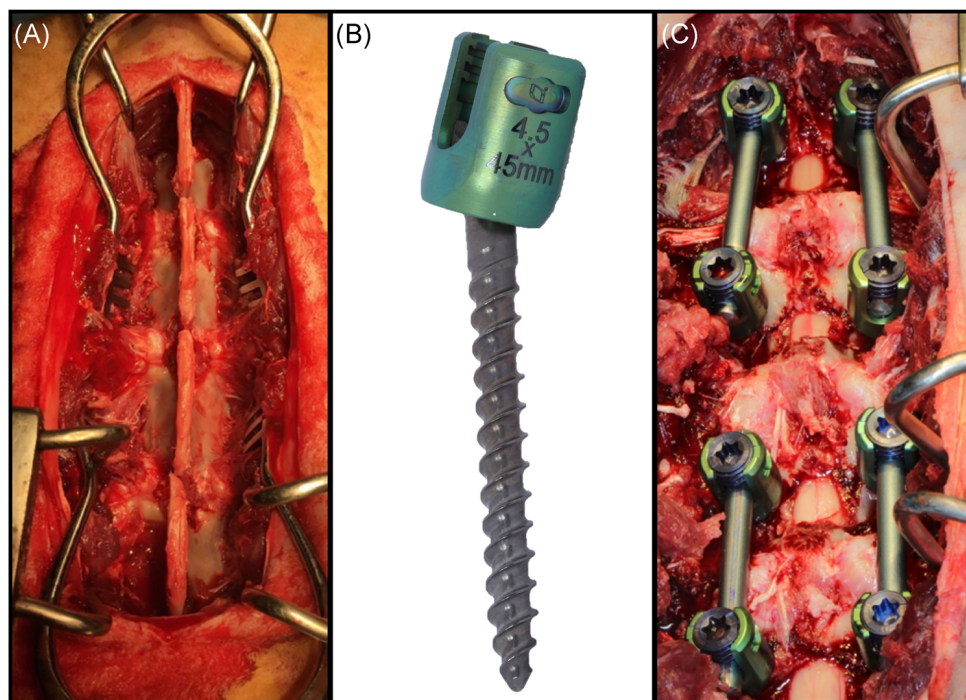


FIGURE 2 A, Digital photo of trans-surgical view of laminectomy, B, 4.5 mm, D, $\times 45$ mm (L) pedicle screw (Nuvasive, San Diego, CA), and C, digital trans-surgical view of pedicle screw placement into lumbar spine [Color figure can be viewed at wileyonlinelibrary.com]

(Nuvasive, San Diego, CA) to enlarge the osteotomy. On the contralateral side, the osteotomy was prepared through the non-subtractive, OD instrumentation (Versah LLC, Jackson, MI) using a pilot drill, 1828 (2.8 mm), and 2838 (3.8 mm). Following preparation of the osteotomy sites, four pedicle screws measuring 4.5 mm in diameter and 45 mm in length were inserted on each side. Each set of screws on L2-L3 and L4-L5 were connected on both sides using titanium rods (Figure 2C). The surgical distribution and fixation were designed to allow direct comparisons between instrumentation methods, where paired level screws were equally destabilized. The surgical site was closed in layers using absorbable suture for the muscles and fascia and 2.0 nylon interrupted suture for the skin. The animals were separated into two groups, four animals set for 6 weeks and four animals set to 12 weeks postoperatively. Cefazolin (500 mg) was administered intravenously preoperatively and postoperatively. Postoperatively, food and water ad libitum were offered. The animals were examined daily for wound healing, and general status, from the first day post-op until time of euthanasia.

Following the necropsy, the vertebrae with implant constructs were removed en bloc. One implant of each level was assigned with its contralateral counterpart to biomechanical and histologic processing, respectively (ie, the rostral and caudal pair of each level to biomechanical and histologic testing, respectively).

2.2 | Mechanical test

In order to measure pullout strength, mechanical testing of all implants was performed using a universal testing machine (Instron

Series 5560 Norwood, MA) with a cross-head speed of 1 mm/s. The results of the biomechanical testing were recorded at the first 10% drop in pull-out force (representative of the initial bone-pedicle screw interface disruption) and analyzed as mean values with the corresponding 95% confidence interval values (mean \pm 95% CI). The interfacial pull-out strength was compared using factors including time (6- and 12-week) as well as surgical insertion method, R and OD.

2.3 | Histological analysis

The bone-implant blocks were gradually dehydrated in a series of alcohol solutions ranging from 70% to 100% ethanol and then embedded in a methyl methacrylate-based resin. Embedded blocks were then cut into sections using a diamond saw (Isomet, 2000; Buehler Ltd, Lake Bluff, IL). The sections were ground on a grinding machine (Metaserv 3000; Buehler, Lake Bluff, IL) under water irrigation with a series of SiC abrasive paper until they were approximately 100 μ m thick, and the samples were then stained in Stevenel's blue and Van Gieson to differentiate the soft and connective tissues (Figure 3). Histology samples were evaluated histomorphometrically using image analysis software (ImageJ, NIH, Bethesda, MD). BAFO was quantified to evaluate the osteogenic parameters around the surface and within the threads by measuring bone growth as a percentage. All histomorphometric testing data are presented as mean values with the corresponding 95% confidence interval values (mean \pm 95% CI). The %BAFO data was analyzed using a linear mixed model with fixed factors of time in vivo (6- and 12-week) and surgical insertion method R and OD.

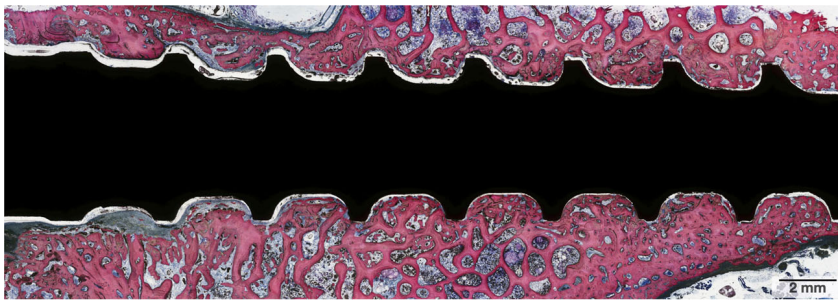


FIGURE 3 Representative longitudinal histological micrograph of the 45 mm (full length) pedicle screw [Color figure can be viewed at wileyonlinelibrary.com]

2.4 | Statistical analysis

All biomechanical and histomorphometric testing data are presented as mean values with the corresponding 95% confidence interval values (mean ± 95% CI). Removal torque and BAFO (%) value data were analyzed using a linear mixed model with a fixed factor of surgical insertion method, R and OD, and time in vivo. All Analyses were completed with IBM SPSS (v23, IBM Corp, Armonk, NY).

3 | RESULTS

3.1 | Mechanical test and histomorphometry

No surgical site showed any signs of inflammation, infection, or failure of the implant throughout the period of healing. Sharp dissection and clinical inspection demonstrated that all devices were integrated with bone and clinically stable. Mechanical pullout interfacial strength collected across all time points delineated no significant difference in outcomes between fixed levels. However, when comparing mechanical stability between OD and R at 6-week, there was significantly greater strength for the OD group vs the R group (Figure 4A). The OD group averaged 387 N, meanwhile the R group averaged 292 N. Furthermore, at the 12-week time point similar results were seen as the OD group had a strength of 312 N and the R group of 212 N (Figure 4A). Overall, when comparing the data irrespective of vertebrae and time point, the OD group had significantly ($P = .05$) greater pullout strength, 349 N relative to the R group 252 N (Figure 4B).

Analysis for integration with respect to BAFO did not yield any significant differences when evaluating as a function of insertion technique (OD vs R) (Figure 5A; $P = .457$) and time in vivo (Figure 5B; $P = .957$). All pedicle screws considered for statistical analysis demonstrated osseointegration upon survey histologic evaluation (Figure 6A,B). Upon further qualitative histologic evaluation of micrographs, both longitudinal (Figure 6A,B) and transverse (Figure 6A.1,B.1), depicted osseointegration of all pedicle screws, with increased evidence of autologous bone particles (“chips”) present in the OD (Figure 6B,B.1) instrumentation. The bone remodeling was extensive in OD instrumentation group at both newly formed bone as well as in bone chips.

4 | DISCUSSION

Indications for lumbar spinal fusion surgery, though still controversial, have seen an expansion toward instability (spondylolisthesis) and

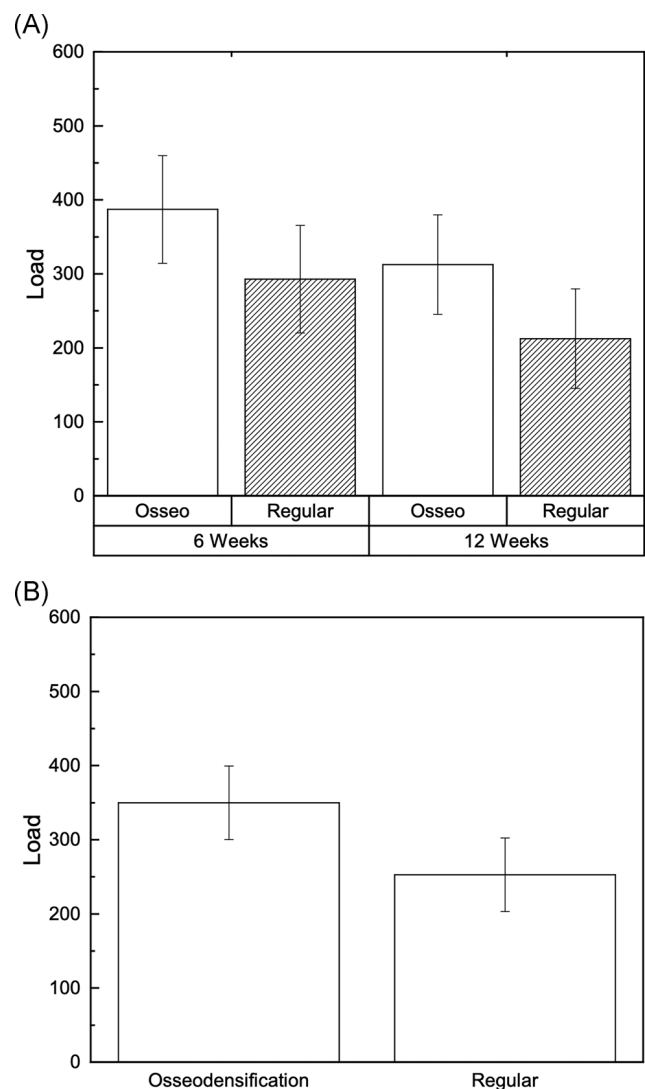


FIGURE 4 Bar graphs presenting the mean removal load (N) ± 95% CI of (A) as function of time and instrumentation, where OD group show significantly greater load bearing capability as compared to the R group at both 6- and 12-week. And (B) mean peak load with corresponding 95% CI independent of time. Letters denote statically homogenous groups. CI, confidence interval; OD, osseodensification; R, regular

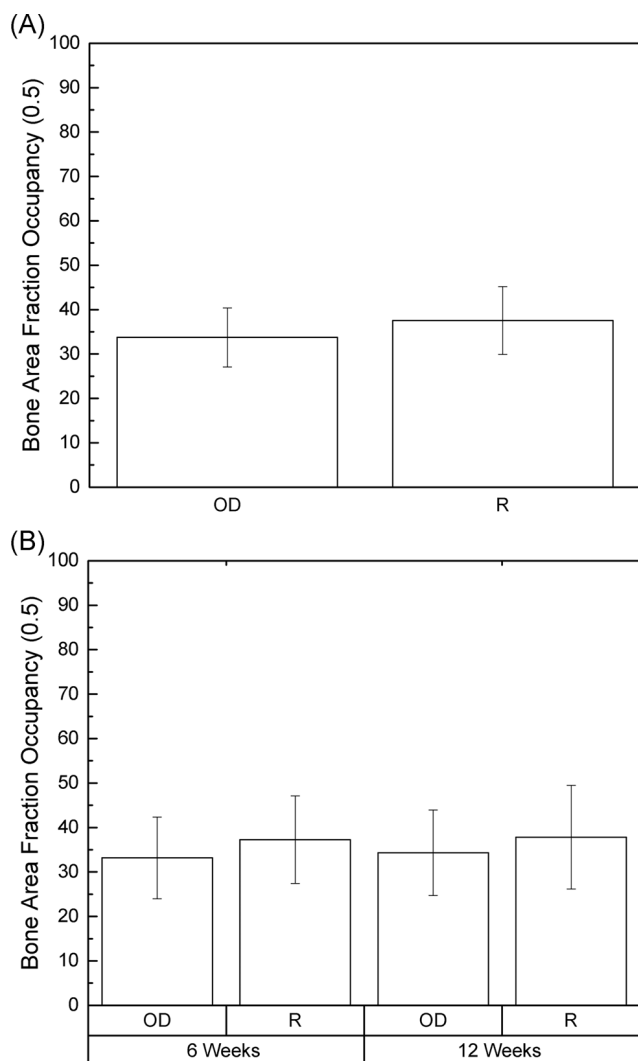


FIGURE 5 Bar graphs presenting the mean BAFO (%) \pm 95%CI of (A) as function of instrumentation (OD vs R) and (B) as function of time and instrumentation. Letters denote statically homogenous groups. BAFO, bone area fraction occupancy; CI, confidence interval; OD, osseodensification; R, regular

deformity (scoliosis and sagittal imbalance) conditions.¹ This increase was recorded mainly among patients aged 65 and older,² whose incidence jumped from 98.3/100 000 in 2004 to 170.3 cases per 100 000 in 2015.¹ Possible factors correlated with such an increase are the availability of improved diagnostic and anesthetic techniques, enabling elective surgery in older and systemically compromised patients, as well as advances in post-operative and rehabilitative care. The positive trend has furthermore been encouraged by the reviewed policies allowed by insurance companies to cover spinal fusion surgery with a broader spectrum of indications.¹⁷

The surgical techniques to obtain a stable lumbar spine fusion have evolved over time. From the first pioneering spinal fusion with silver wire bounding described by Handra in 1891, there has been a progressive evolution of techniques and materials over time.¹⁸ The application of biomechanical concepts to explain pathogenesis of both the spinal instability and internal fixation failures produced a

flourishing of different approaches (ie, anterior vs posterior fusion), osteosyntheses, and grafting materials used in different combinations.¹⁹ Despite all the efforts, pseudarthrosis and pedicle screw failure remain an ever-returning issue, especially in presence of osteoporosis and older patients.^{6,9} In an attempt to limit these complications, and the correlated costs of salvage interventions and/or chronic assistance, research has been focused to identify bone graft substitutes and osteogenic enhancers (rhBMP2), while a multitude of different materials (polyether ether ketone cages²⁰), geometries (polyaxial, fenestrated, expandable pedicle screws^{10,11,21}), and engineered surface technologies (coated screws¹²) have been proposed to resolve the hardware failure.

In contrast to the broad spectrum of osteosynthesis implants proposed and tested, little attention has been given to the instrumentation used for placement of the osteosynthesis devices. Primary objective of this study is to test an alternative osseodensification drilling technique for the placement of multiaxial pedicle screws, a technique developed and successfully applied in dental rehabilitation for osseointegrated implants.¹⁴ The OD technique is a non-extractive technique, meaning that the bone debris derived from the drilling action is not pulled away and discarded by the shaping drill, but centrifugally pushed and compacted against the wall of the drilled hole, enhancing bone density in the critical implant-bone interface area. The process relies on the peculiar macrogeometry of the shaping drills that, rotating in counterclockwise direction, exercise simultaneous actions of bone cutting and compacting action of the bone particulate, the compaction and autografting process being more prominent when the drilling is performed in counterclockwise direction at medium-high speed (800-1100 rpm) through a bouncing-pumping motion under copious irrigation. Animal and clinical studies proved that the osseodensification drilling process was particularly effective on improving the stability and overall success of implants placed on low density bone (type 4), such as the atrophic maxillary bone or iliac crest cancellous bone, by increasing primary biomechanical stability and promoting faster and more robust osteointegration due to the autografting of bone particles between the implant threads.^{7,14,22-27}

The present study, comparing the R and OD instrumentation on the same vertebra in a split model and utilizing identical pedicle screws on both sides, allowed for a paired comparison of each technique minimizing potential bias from anatomical variation (ie, bone density, volume and shape), screw geometry, and potential spine biomechanic differences as a function of fused level.

If the OD technique is an effective method of obtaining superior biomechanical stability of the pedicle screws, it would further enhance spine stabilization in patients with low density bone (ie, osteoporosis). Osteoporosis is a well-known predisposing factor for screw failure with 62% rate of screw loosening,⁶ and is particularly relevant considering the increasing spinal fusion trend in older patients.

In light of the uniformity of the bone anatomy, osteosynthesis features, and biomechanics conditions, it is not surprising that the histometric analysis showed no statistical differences in BAFO between R and OD groups. Worth noting is the OD group presented increased presence of bone particulate between the screw threads

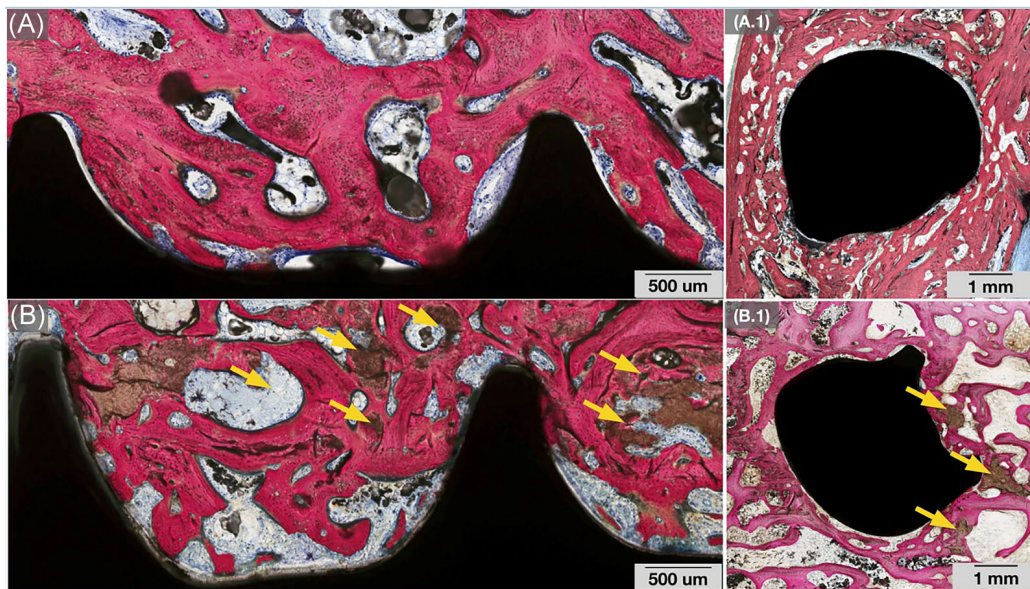


FIGURE 6 Representative optical histological micrographs from each instrumentation group, (A and A.1) conventional and (B and B.1) non-subtractive, OD instrumentation. Yellow arrows illustrate autologous bone “chips” which function as remodeling sites. OD, osseodensification [Color figure can be viewed at wileyonlinelibrary.com]

with more extensive bone remodeling compared to the conventional, R, group, a feature that likely accounted for the higher and sustained biomechanical fixation over the course of the study.

In terms of the mechanical pull-out test, the results showed increased values in the OD group compared with the R drilling group at both the 6 and 12 weeks intervals; with respect to the reported interfacial fracture pull-out strength values, 390 N and 300 N at 6 weeks for OD and R respectively and 320 N (OD) and 290 N (R) at 12 weeks, it is to be noticed how they are significantly lower compared with those reported in other similar studies, such as the values ranging from 662 N to 4235 N reported by Easley et al⁵ on an ovine model, or those by Leichtle et al²¹ on human osteoporotic vertebrae. Such difference is accounted by the method utilized for the present study, where the interfacial initial fracture value was used (an initial drop of 10% of the maximum value) instead of the full screw pullout value.^{5,21}

The rationale for utilizing the measurement was to determine the initial loss of contact between the screw threads and the bone at the interface, representative of initial screw failure rather than its complete avulsion, the latter process being potentially spoiled by the angulation of the screw and/or by irregular fracture line occurring as the interface and surrounding bone are disrupted by mechanical testing.

Despite the advantages offered by the ovine model, such as its similarity in body weight, bone mineral composition, and bone metabolic rate with humans, the present study did present with several limitations: (a) no bone mineral density assessment on the vertebrae was conducted, a known contributing factor to determine the screw pull-over entity; (b) considering the young age and healthy status of the animals, the model was not representative of a human osteoporotic vertebra, with little translatability of the results on a realistic clinical scenario; (c) despite our attempt to destabilize the lumbar spine by performing bilateral laminectomies and facet disruptions,

the high quality bone, discs and ligaments of the model likely minimized the poor biomechanical conditions encountered in the most biomechanically compromised clinical settings (ie, osteoporosis, degenerative disc/ligaments pathology, severe spinal instability); (d) while the split design allows for maximum statistical power with reduced number of animals, it carries the intrinsic disadvantage of having the control and experimental groups implanted on opposite sides of the same vertebrae, a condition that involve the unavoidable mutual influence on the outcome (ie, the lack of stability on one side will determine an overload on the contralateral fixation system, potentially biasing the overall results). The fact that none of our pedicle screws showed gross and/or histologic signs of failure likely reduced the risk of such a bias, nonetheless the results obtained should be validated in a future study that would compare R and OD group independently with a standard case-control design.

This study is, to the best of our knowledge, one of the few focused on the instrumentation aspect of the procedure in order to improve the success rate of the lumbar spinal stabilization by multi-axial pedicle screws, and probably the first applying the osseodensification drilling technique in this setting. Successful lumbar spinal internal fixation was obtained in all the animals, a remarkable result that confirmed the validity of the model and the reliability of the osteosynthesis under mechanical stress conditions. More studies are warranted to replicate this study design on a model more representative of a pathologic lumbar spine.

5 | CONCLUSION

The osseodensification drilling method, applied in the setting of a posterior lumbar spine fixation by multi-axial screws and rods in an

ovine model, proved to establish and maintain superior biomechanically fixation to the conventional instrumentation.

ACKNOWLEDGMENTS

The authors would like to thank Versah for technical support in providing drill bits and partial financial support and Nuvasive for technical support with instrumentation and hardware material. The devices that are subject of this manuscript are FDA-approved or approved by corresponding national agency for this indication.

AUTHOR CONTRIBUTIONS

Study design and surgical procedures: AT, PGC, and JHH. Mechanical test and hystomorphometric analysis: LW and PELP. Statistical analysis: LW. All authors have read and approved the submitted manuscript.

ORCID

Andrea Torroni  <http://orcid.org/0000-0001-7507-6331>

Lukasz Witek  <http://orcid.org/0000-0003-1458-6527>

Jacques Henri Hacquebord  <http://orcid.org/0000-0003-1829-1195>

REFERENCES

- Martin BI, M S, Spina N, Spiker WR, Lawrence B, Brodke DS. Trends in lumbar fusion procedure rates and associated hospital costs for degenerative spinal diseases in the United States, 2004-2015. *Spine*. 2018;43:705-711. in press.
- Deyo RA, Gray DT, Kreuter W, Mirza S, Martin BI. United States trends in lumbar fusion surgery for degenerative conditions. *Spine (Phila Pa 1976)*. 2005;30(12):1441-1445.
- Martin BI, Mirza SK, Franklin GM, Lurie JD, MacKenzie TA, Deyo RA. Hospital and surgeon variation in complications and repeat surgery following incident lumbar fusion for common degenerative diagnoses. *Health Serv Res*. 2013;48(1):1-25.
- Pihlajamaki H, Myllynen P, Bostman O. Complications of transpedicular lumbosacral fixation for non-traumatic disorders. *J Bone Joint Surg Br*. 1997;79(2):183-189.
- Easley J, P C, Palmer R, et al. Biomechanical and hystomorphometric assessment of a novel screw retention technology in an ovine lumbar fusion model. *Spine J*. 2018;18:2302-2315. in press.
- El Saman A, Meier S, Sander A, Kelm A, Marzi I, Laurer H. Reduced loosening rate and loss of correction following posterior stabilization with or without PMMA augmentation of pedicle screws in vertebral fractures in the elderly. *Eur J Trauma Emerg Surg*. 2013;39(5):455-460.
- Lopez CD, Alifarag AM, Torroni A, et al. Osseodensification for enhancement of spinal surgical hardware fixation. *J Mech Behav Biomed Mater*. 2017;69:275-281.
- Coelho PG, Jimbo R. Osseointegration of metallic devices: current trends based on implant hardware design. *Arch Biochem Biophys*. 2014;561:99-108.
- Paré PE, Chappuis JL, Rampersaud R, et al. Biomechanical evaluation of a novel fenestrated pedicle screw augmented with bone cement in osteoporotic spines. *Spine (Phila Pa 1976)*. 2011;36(18):E1210-E1214.
- Wu Z, Gong F, Liu L, et al. A comparative study on screw loosening in osteoporotic lumbar spine fusion between expandable and conventional pedicle screws. *Arch Orthop Trauma Surg*. 2012;132(4):471-476.
- Cook SD, Salkeld SL, Whitecloud TS 3rd, Barbera J. Biomechanical evaluation and preliminary clinical experience with an expansive pedicle screw design. *J Spinal Disord*. 2000;13(3):230-236.
- Sanden B, Olerud C, Johansson C, Larsson S. Improved bone-screw interface with hydroxyapatite coating: an in vivo study of loaded pedicle screws in sheep. *Spine (Phila Pa 1976)*. 2001;26(24):2673-2678.
- Takigawa T, Tanaka M, Konishi H, et al. Comparative biomechanical analysis of an improved novel pedicle screw with sheath and bone cement. *J Spinal Disord Tech*. 2007;20(6):462-467.
- Oliveira PGFP, Bergamo ETP, Neiva R, et al. Osseodensification outperforms conventional implant subtractive instrumentation: A study in sheep. *Mater Sci Eng C Mater Biol Appl*. 2018;90:300-307.
- Lahens B, Neiva R, Tovar N, et al. Biomechanical and histologic basis of osseodensification drilling for endosteal implant placement in low density bone. An experimental study in sheep. *J Mech Behav Biomed Mater*. 2016;63:56-65.
- Coelho PG, Suzuki M, Marin C, et al. Osseointegration of plateau root form implants: unique healing pathway leading to Haversian-like long-term morphology. In: Bertassoni LE, Coelho PG, eds. *Engineering Mineralized and Load Bearing Tissues*. Cham: Springer International Publishing; 2015:111-128.
- Martin BI, F G, Deyo RA. How do coverage policies influence practice patterns, safety, and cost of initial lumbar fusion surgery? A population-based comparison of workers' compensation systems. *Spine J* 2013;14:1237-1246.
- Lf P. *Orthopedics: A History and Iconography*. San Francisco CA: Norman Publishing; 1993.
- de Kunder SL, R K, Caelers IJM, de Bie RA, Koehler PJ, van Santbrink H. Lumbar interbody fusion A historical overview and a future perspective. *Spine*. 2018;43(16):1161-1168.
- Brantigan JW, S A, Lewis ML, Quinn LM, Persenaire JM. Lumbar interbody fusion using the Brantigan I/F cage for posterior lumbar interbody fusion and the variable pedicle screw placement system: two-year results from a food and drug administration investigational device exemption clinical trial. *Spine*. 2000;25(11):1437-1446.
- Leichtle CI, L A, Rothstock S, et al. Pull-out strenght of cemented solid versus fenestrated pedicle screws in osteoporotic vertebrae. *Bone Joint Res*. 2016;5:419-426.
- Alifarag AM, Lopez CD, Neiva RF, Tovar N, Witek L, Coelho PG. Atemporal osseointegration: early biomechanical stability through osseodensification. *J Orthop Res*. 2018;36(9):2516-2523.
- Lahens B, Lopez CD, Neiva RF, et al. The effect of osseodensification drilling for endosteal implants with different surface treatments: a study in sheep. *J Biomed Mater Res B Appl Biomater*. 2019;107(3):615-623.
- Lahens B, Neiva R, Tovar N, et al. Biomechanical and histologic basis of osseodensification drilling for endosteal implant placement in low density bone. An experimental study in sheep. *J Mech Behav Biomed Mater*. 2016;63:56-65.
- Tian JH, Neiva R, Coelho PG, et al. Alveolar ridge expansion: comparison of osseodensification and conventional osteotome techniques. *J Craniofac Surg*. 2019;30(2):607-610.
- Witek L, Alifarag A, Tovar N, et al. Osteogenic parameters surrounding trabecular tantalum metal implants in osteotomies prepared via osseodensification drilling. *Med Oral Patol Oral Cir Bucal*. 2019;24(6):e764-e769.
- Witek L, Neiva R, Alifarag A, et al. Absence of healing impairment in osteotomies prepared via osseodensification drilling. *Int J Periodontics Restorative Dent*. 2019;39(1):65-71.

How to cite this article: Torroni A, Lima Parente PE, Witek L, Hacquebord JH, Coelho PG. Osseodensification drilling vs conventional manual instrumentation technique for posterior lumbar fixation: Ex-vivo mechanical and histomorphological analysis in an ovine model. *J Orthop Res*. 2020;1-7. <https://doi.org/10.1002/jor.24707>