

# Preoperative Evaluation and Treatment Planning. Zygomatic Implant Critical Zone (ZICZ) Location



Carlos Aparicio, MD, DDS, MSc, MSc, DLT, PhD <sup>a,\*</sup>, Roberto López-Píriz, MD, DDS, PhD <sup>b</sup>, Miguel Peñarrocha, DDS, PhD, MD <sup>c</sup>

## KEYWORDS

• Zygomatic implants evaluation • ZAGA • Anatomy-guided approach • Patient-specific therapy • Zygomatic implant critical zone

## KEY POINTS

- A systematic preoperative evaluation is an essential basis to identify challenges, risks, and limitations to establish an accurate treatment plan.
- The understanding of anatomic differences provides the framework for the treatment planning design.
- A complete treatment planning, including the visualization and prevention of late complications, constitutes the strategy for predictable, functional, and esthetic outcomes.

## Introduction

Maxillary atrophy usually represents the final outcome of multiple failed conservative dental treatments, regenerative approaches, or rehabilitation procedures such as grafting or implant placement. The rehabilitation of the severely atrophic edentulous maxilla entails both a huge challenge for the practitioner and the last opportunity for the patient to have a fixed set of teeth, to recover esthetics and masticatory function.<sup>1,2</sup>

Clinicians face several important decisions in the planning and delivery of oral rehabilitation anchored on zygomatic implants. Nevertheless, this surgery demands, in addition to a high level of surgical experience and skills, a meticulous patient-centered evaluation to<sup>2</sup>:

- Address the patient's concerns and goals
- Minimize risks and adverse events
- Reduce the treatment duration and the financial cost
- Adequately inform the patient of the potential benefits and risks of this treatment
- Provide the patient with an understanding of appropriate treatment alternatives
- Simplify treatment when possible.

This treatment should be performed knowing one's own limitations and seeking consultation whenever appropriate.

These goals are achieved using a systematic preoperative evaluation of the implicit risks and a profound knowledge of the maxilla anatomy. Only based on these elements, one can set up a centered patient's welfare, anatomy-guided treatment planning.

## Anatomic considerations

Profound knowledge of the anatomy is required, including the following structures (Fig. 1):

- Alveolar process of the maxilla
- Maxillary anterior wall
- Zygomatic process of the maxilla
- Maxillary left and right, anterior ethmoidal, posterior ethmoidal, sphenoidal, frontal sinuses, and ostium
- Tuberosity/pterygoid process
- Zygomatic bone
- Proximal soft tissues susceptible to being damaged during the drilling procedure or flap raising

## The zygoma anatomy-guided classification

When planning the osteotomy for a zygomatic implant, it is crucial to understand that a zygomatic implant may adopt different trajectories. This will depend on the location of the coronal entrance, and on adapting the surgical procedures and implant designs to each patient's anatomic characteristics. This is aimed at reducing early and late complications.

Based on a cross-sectional study of 200 sites, a classification system comprising 5 basic anatomic groups named from ZAGA

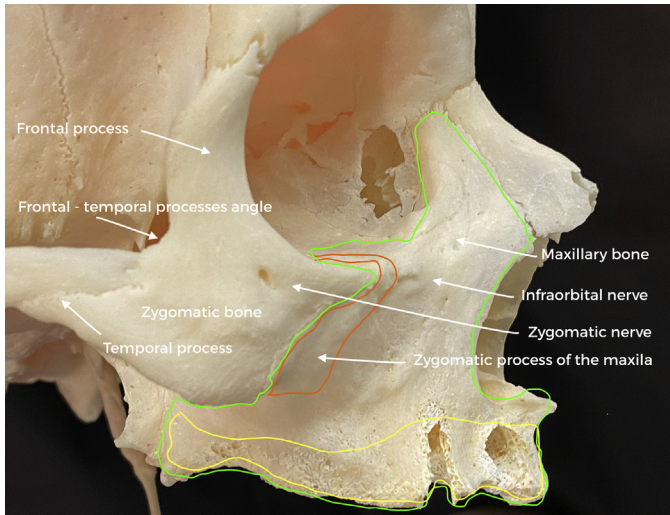
<sup>a</sup> Hepler Bone Clinic, ZAGA Center Barcelona, Roman Macaya, 22-24, Barcelona 08022, Spain

<sup>b</sup> Advanced Oral Surgery Institute - ZAGA Center Scientific Partner CSIC, C/Fray Luis de León 14, local, Madrid 28012, Spain

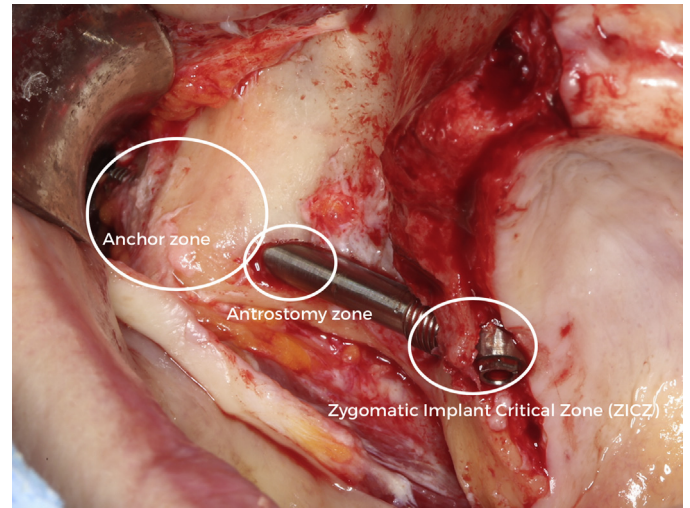
<sup>c</sup> ZAGA Center Scientific Partner - Universidad Valencia, University of Valencia, Gascó Oliag, 1, Valencia 46021, Spain

\* Corresponding author.

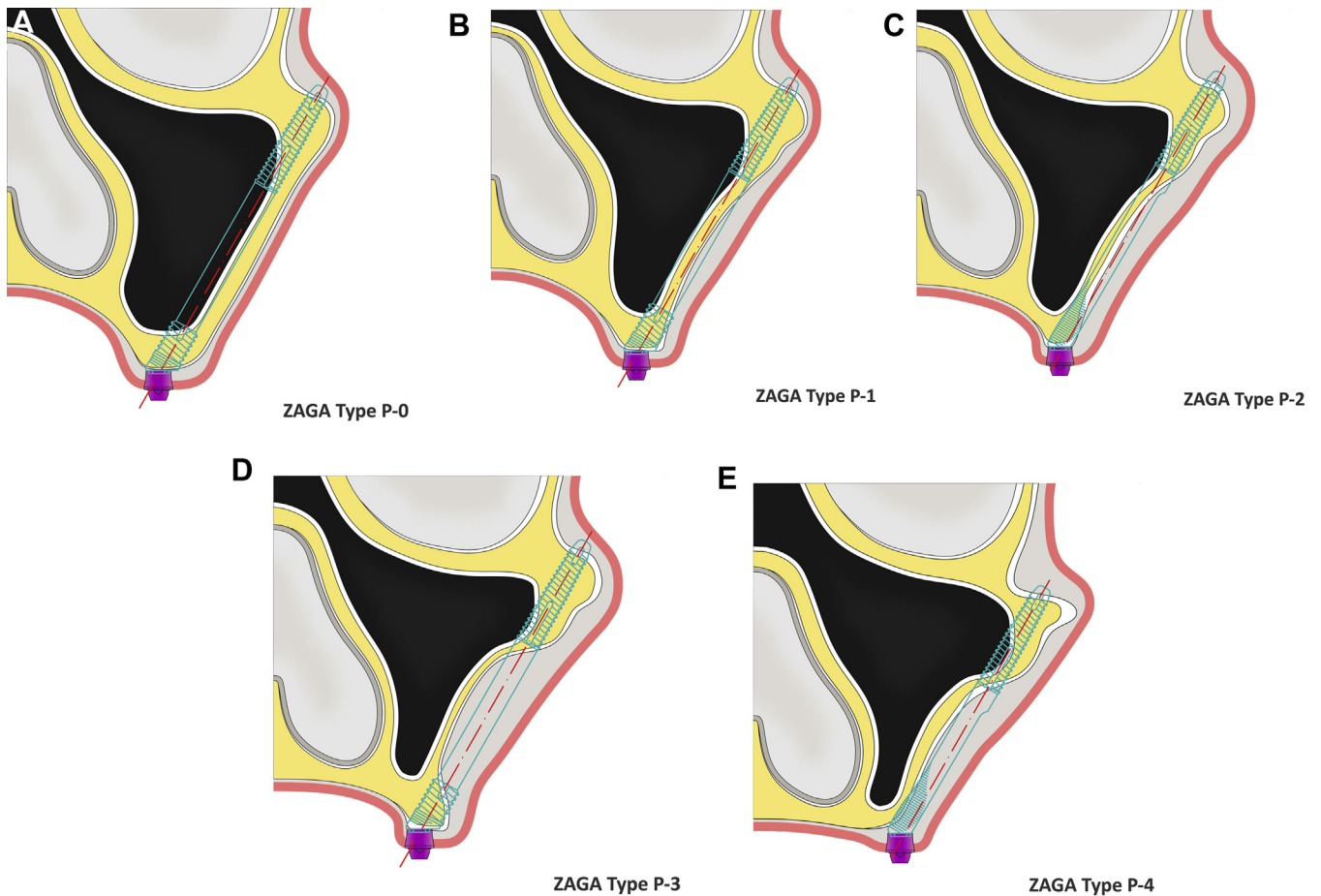
E-mail address: [carlos.aparicio@zagacenters.com](mailto:carlos.aparicio@zagacenters.com)



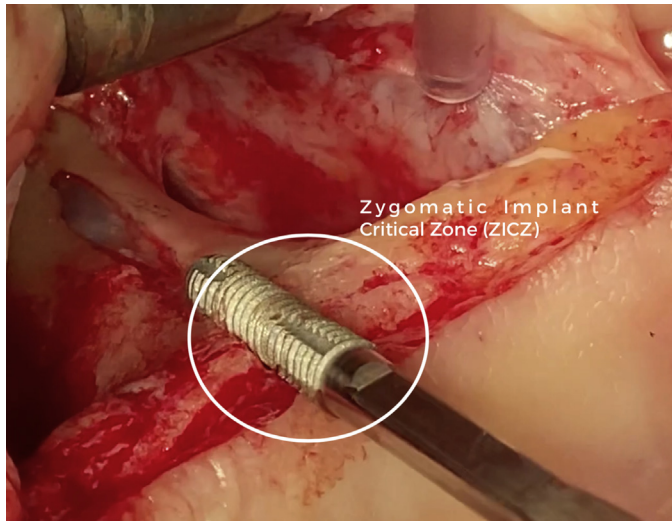
**Fig. 1** Maxillary bone (green line). Zygomatic process of the maxilla (orange). Located at the separation of the maxilla and zygoma surfaces. Its geometry and curvature are crucial parameters to determine the antrostomy location in an extramaxillary placed implant. Residual alveolar process (yellow) architecture is a key factor to plan where the ZICZ will be located.



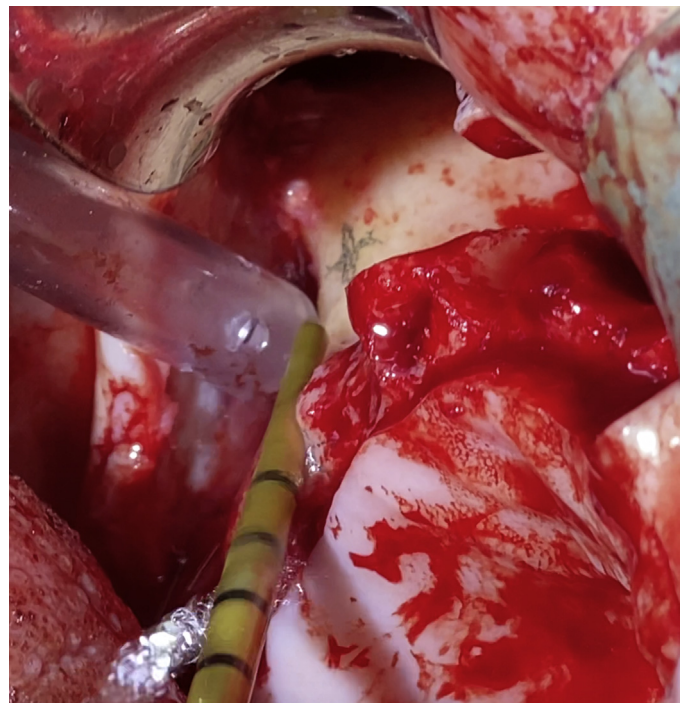
**Fig. 3** The ZAGA zones.



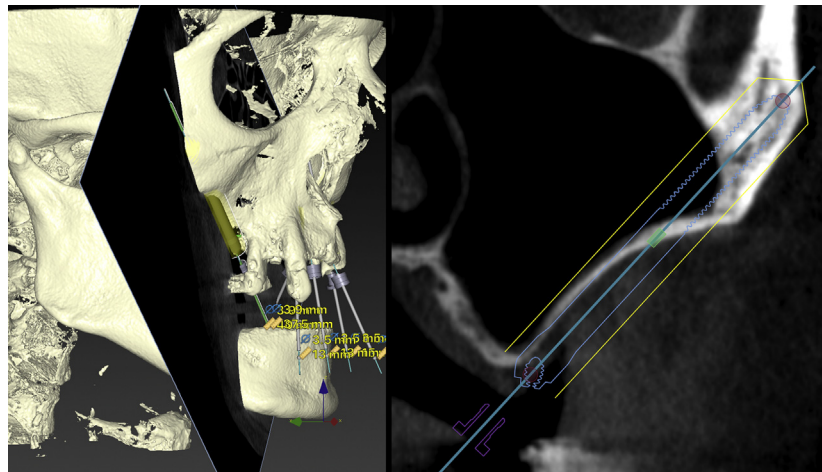
**Fig. 2** ZAGA Classification for the posterior zygomatic implant. The ZAGA Concept implies that in accordance to the amount of residual alveolar bone and anatomic characteristics the implant path will vary from the total intrasinus one (A) to the more or less partially intrasinus (B,C); the intra-alveolar, extramaxillary wall (D); or the extra-alveolar and extramaxillary wall (E).



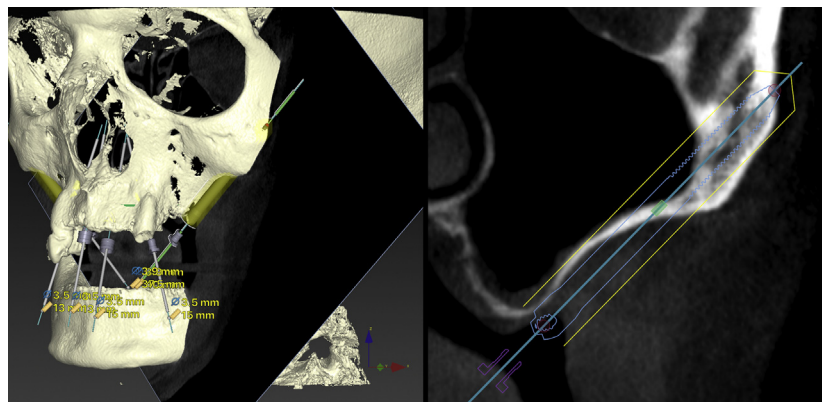
**Fig. 4** The zygomatic Implant Critical Zone (ZICZ) is determined by the relationship between the implant alveolar bone and covering soft tissue.



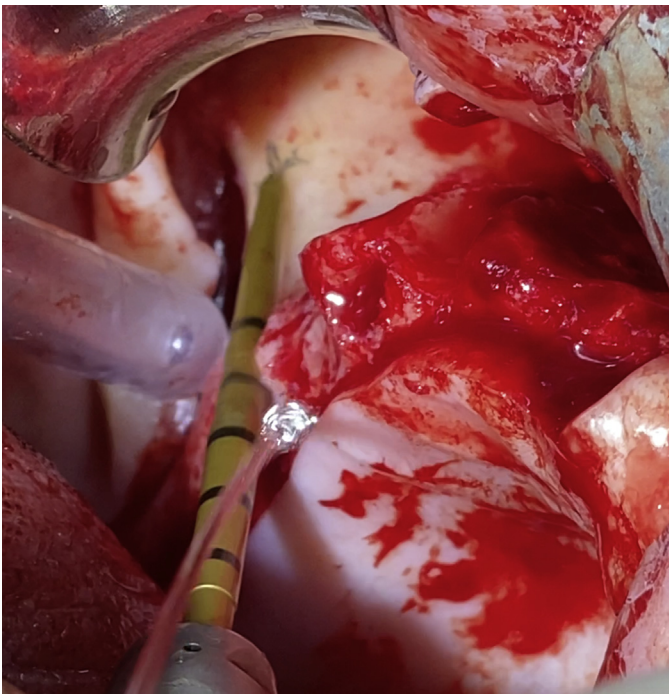
**Fig. 7** Case 1. 3- H.CH- R lateral osteotomy. After marking the coronal and the antrostomy spots A drill from Versah.com is being used for a precise lateral cutting.



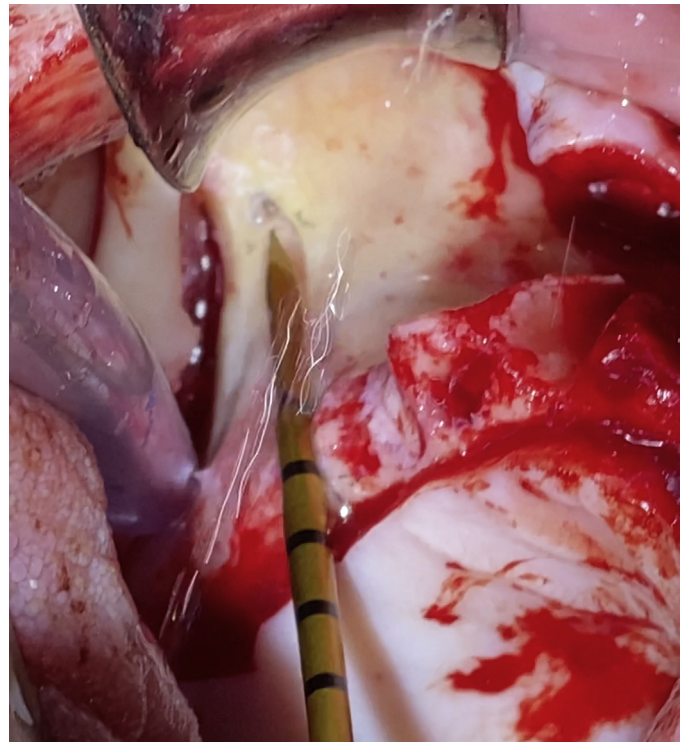
**Fig. 5** Case 1. 1- H.CH- R Planning. The case of an atrophic posterior maxilla is illustrated. Instead of penetrating a thin sinus floor, the right implant path planning is being shifted to the buccal side.



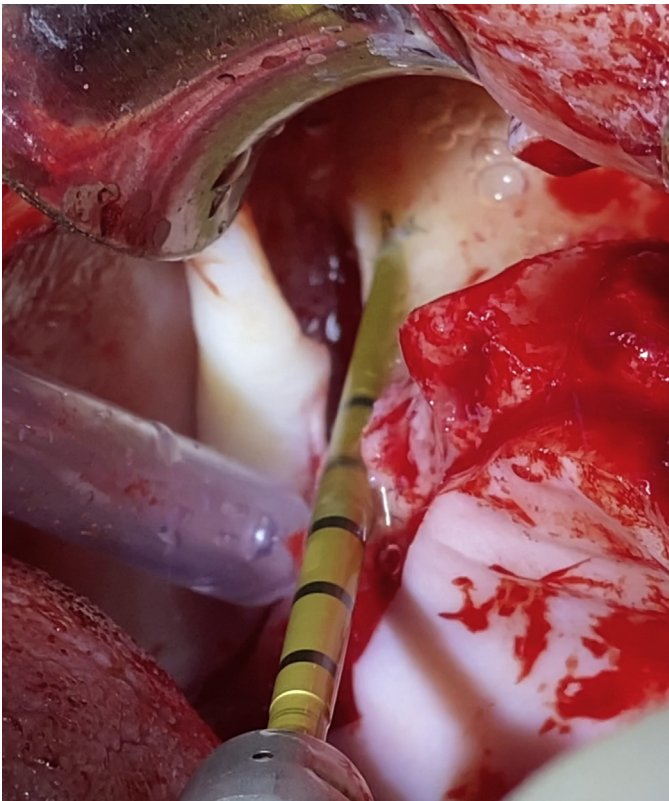
**Fig. 6** Case 1. 2- H.CH- L planning. The left side is also extremely atrophied. An extramaxillary path has been chosen.



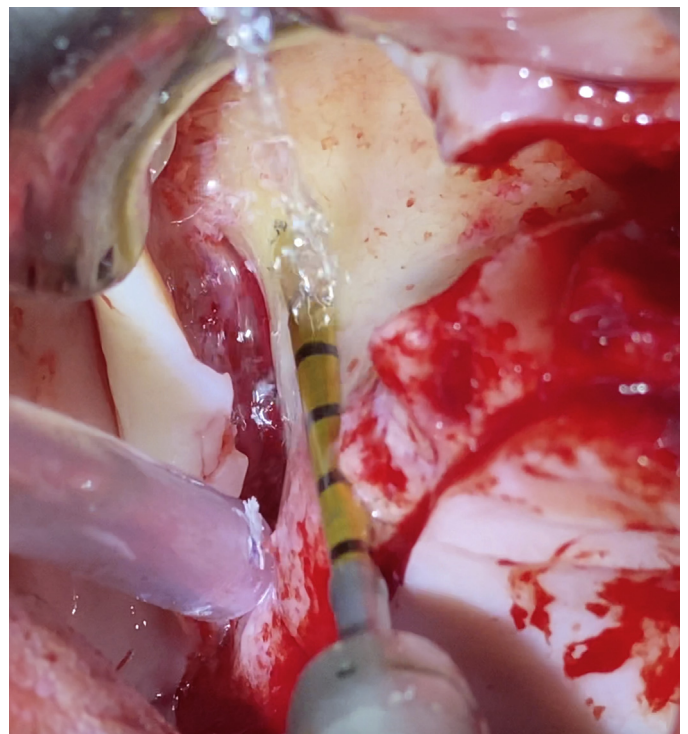
**Fig. 8** Case 1. 4- H.CH- R lateral osteotomy 2. The Versah drill is being used in a clockwise direction to prepare a lateral channel on the alveolar bone and maxillary wall with total respect for the sinus lining.



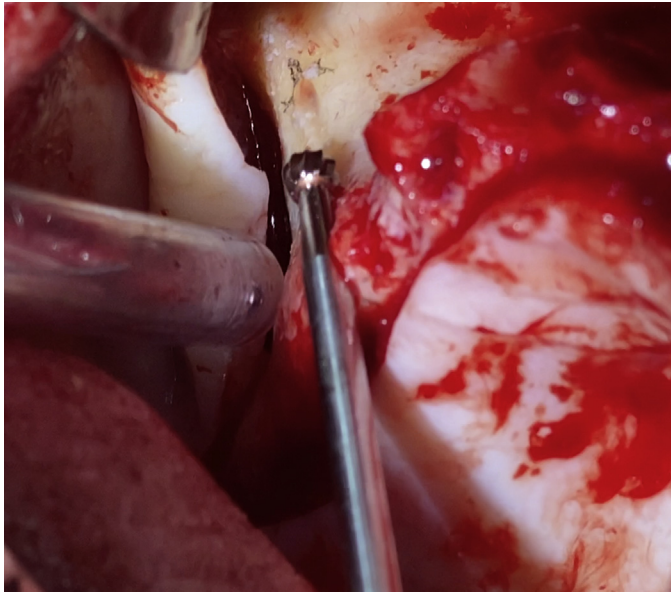
**Fig. 10** Case 1. 6- H.CH- R Sword antrostomy.<sup>1</sup> To minimize eventual heating of the dense zygomatic bone, a "sword" type drill from [Versah.com](http://Versah.com) is being used.



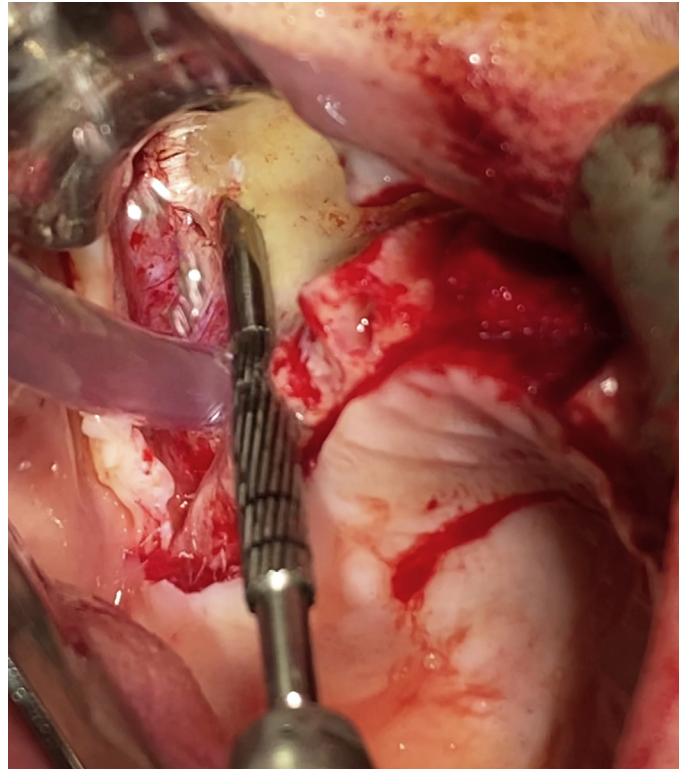
**Fig. 9** Case 1. 5- H.CH- R lateral osteotomy 3. Using a back and forward movement of the Versah Zygo drill, a notch has been performed on the zygomatic maxillary process.



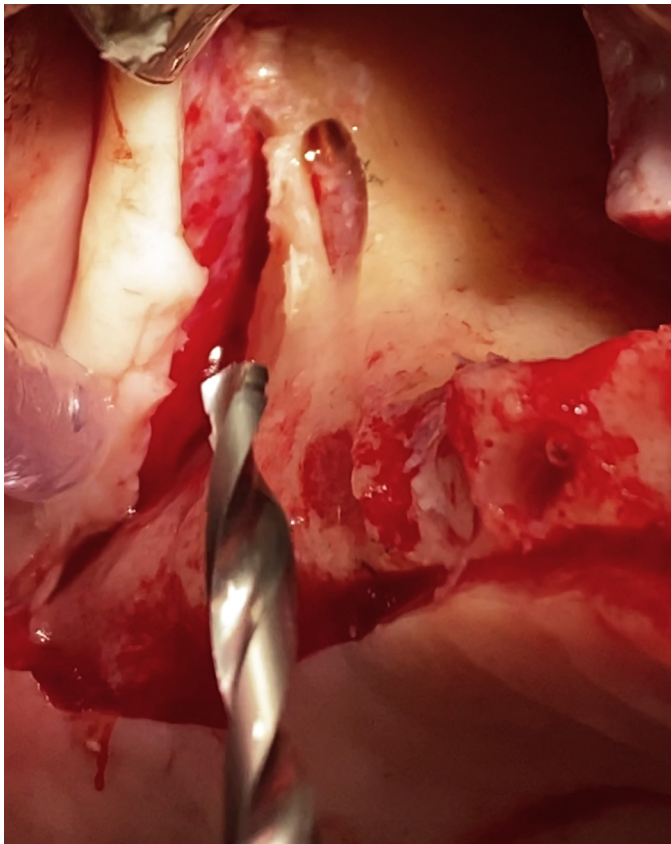
**Fig. 11** Case1. 7-H.CH-R antrostomy. The Versah spear drill is used in the presence of hard Zygomatic bone as initial drill before the round bur. The spear drilling is stopped when reaching the second zygomatic cortical.



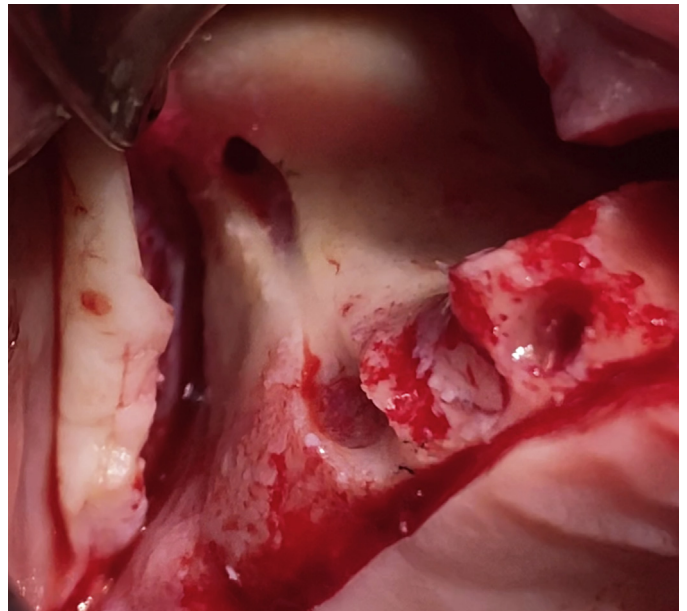
**Fig. 12** Case 1. 8- H.CH- R round bur. The round bur tail may slide back and forward to bevel the bony at the antrostomy zone.



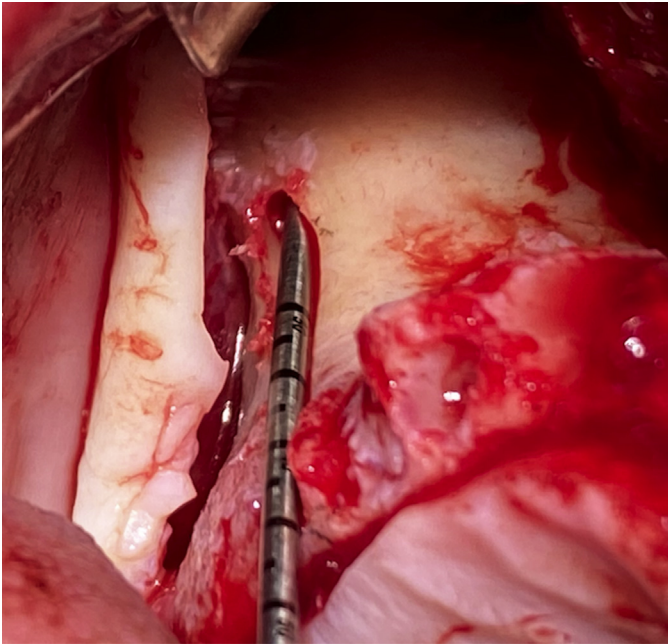
**Fig. 14** Case 1. 10- H.CH- R final lateral osteotomy. A specially designed lateral cutting drill, from Straumann AG, with progressive diameter, was used to enlarge the osteotomy until reaching 4 mm of channel diameter at the ZICZ.



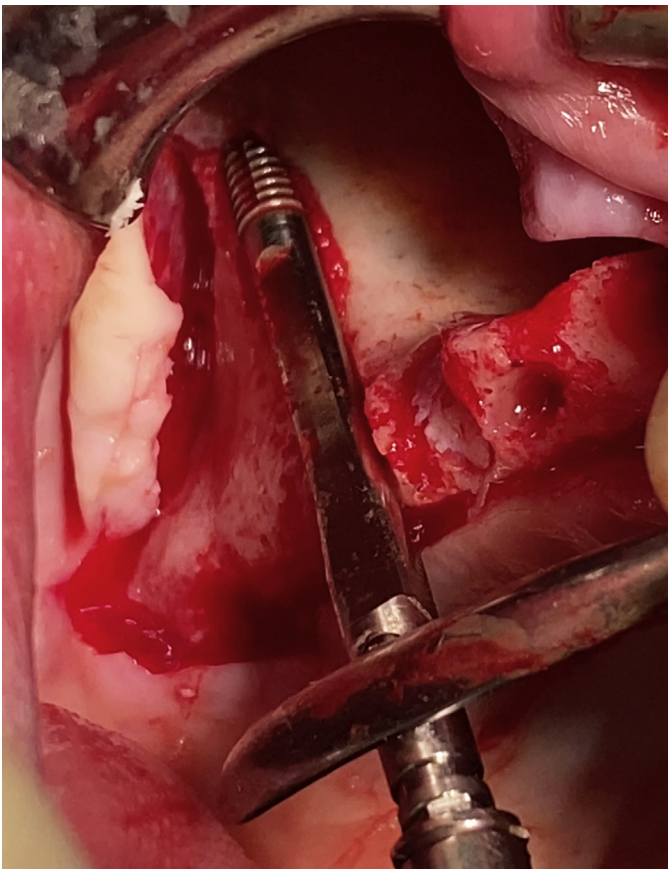
**Fig. 13** Case 1. 9- H.CH- R twist drill.<sup>2</sup> A stepped twist drill of 2.9 mm diameter from Straumann AG was used to enlarge the osteotomy.



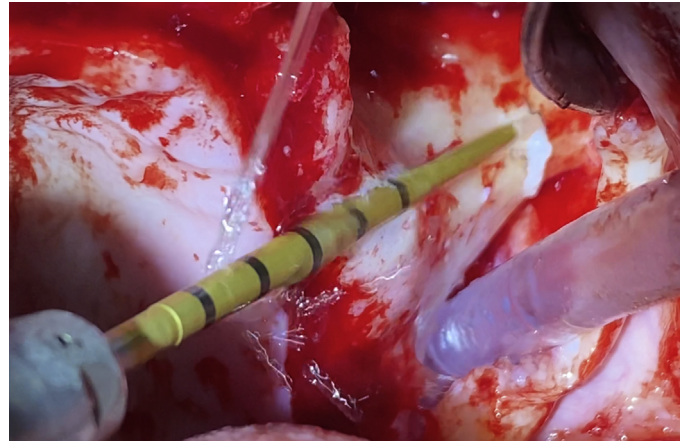
**Fig. 15** Case 1. 11- H.CH- R osteotomy.<sup>2</sup> A ZAGA minimally invasive osteotomy has been achieved. Membrane transparency can be seen at the ZICZ.



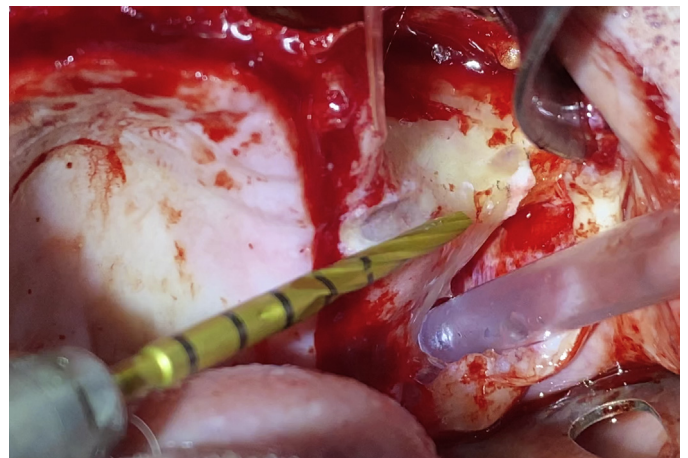
**Fig. 16** Case 1. 12- H.CH- R measuring. A hook-ended gauge is used to determine implant length.



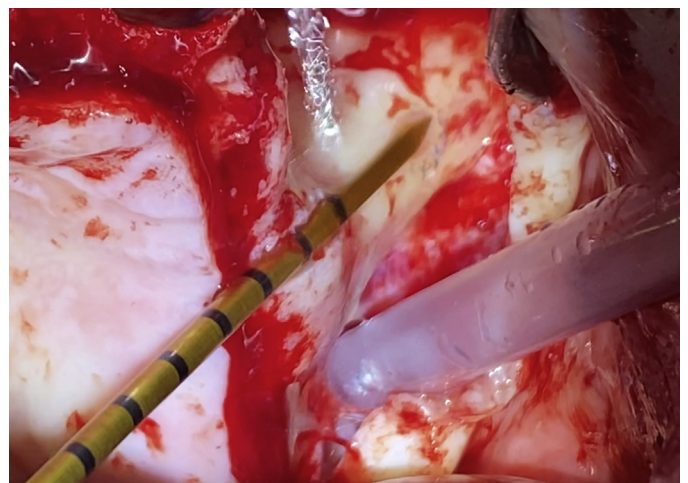
**Fig. 17** Case 1. 13- H.CH- R implant insertion. A Straumann ZAGA Flat zygomatic implant design, totally matching the prepared osteotomy, is being screwed on the zygomatic bone.



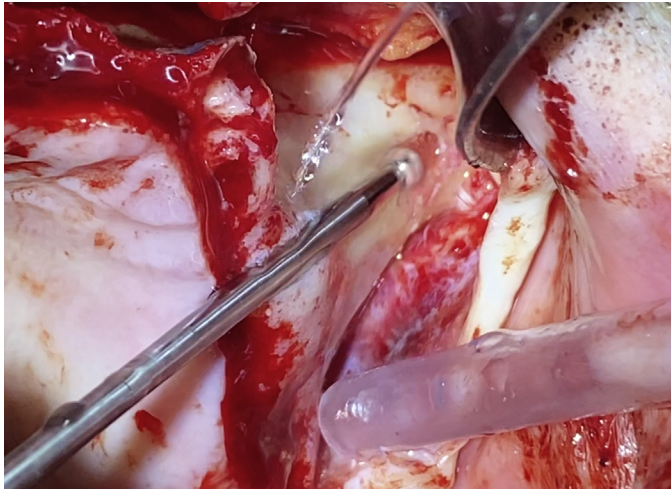
**Fig. 18** Case 1. 14- H.CH- L lateral osteotomy.<sup>1</sup> The left channel is being carved using a 2 mm diameter Versah Zygo drill.



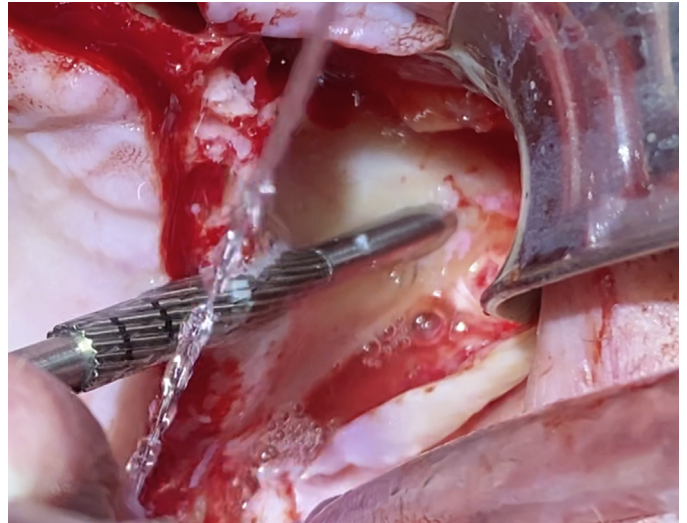
**Fig. 19** Case 1. 15- H.CH- L lateral osteotomy.<sup>2</sup> Following the pencil marks, the 2.5 mm diameter Versah Zygo drill has prepared a smooth channel and the initial notch for the antrostomy.



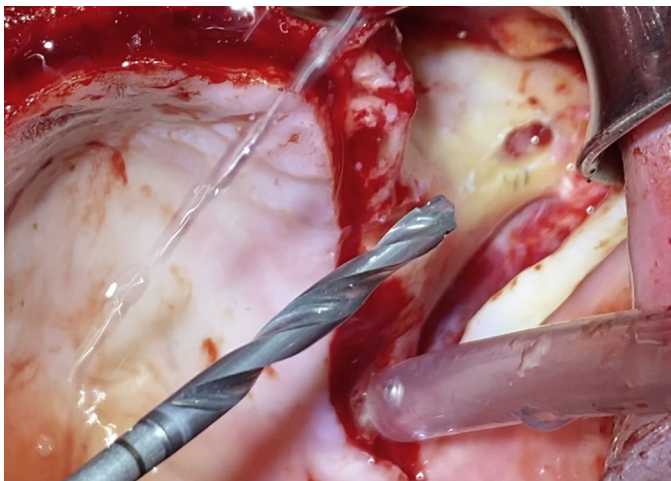
**Fig. 20** Case 1. 16- H.CH- L Spear antrostomy. The spear type zygo bur is used for a predrilling in dense zygomatic bone previous to the 2.9 mm diameter twist drill.



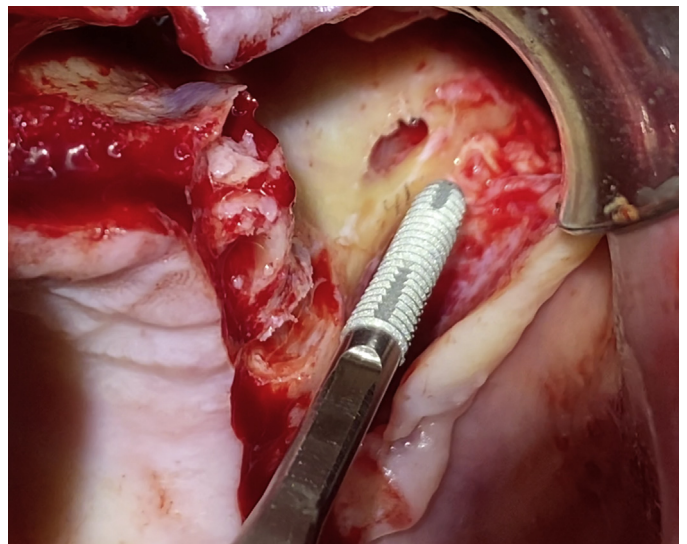
**Fig. 21** Case 1. 17- H.CH- L round bur.<sup>2</sup> As the diameter of the spear drill is thinner than the twist drill, the round bur is used for enlarging the cortical entrance so that a precise osteotomy direction can be maintained.



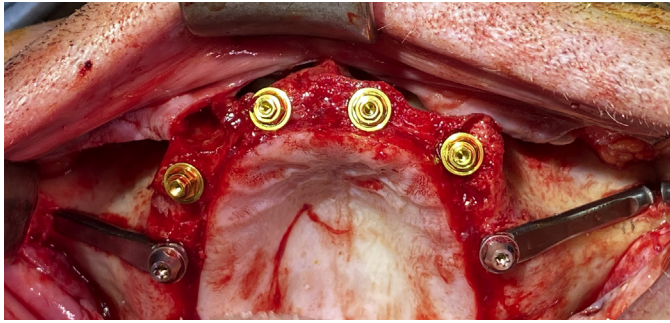
**Fig. 23** Case 1. 19- H.CH- L final lateral osteotomy. A ZAGA progressive and guided lateral cutting drill is being used to prepare the implant neck bed in the ZICZ.



**Fig. 22** Case 1. 18- H.CH- L twist drill. A stepped 2.7 to 2.9 mm diameter Straumann AG twist drill is being used to accomplish the ZAGA minimally invasive osteotomy.



**Fig. 24** Case 1. 20- H.CH- L implant insertion. A zygomatic tapered ZAGA Flat design from Straumann is faced to the left side osteotomy.



**Fig. 25** Case 1. 25- H.CH- occlusal with implants.<sup>2</sup> The post-operative occlusal view shows a perfect osteotomy sealing, maximizing the bone to implant contact on both sides.

0 to 4 was proposed by Aparicio.<sup>3</sup> Five basic skeletal forms of the zygomatic buttress and alveolar crest complex and implant trajectories were identified. Anatomic intraindividual patient differences were found in 58% of the population (Fig. 2). It is believed that the proposed system is useful for classifying zygomatic implant cases for therapy planning and scientific follow-up purposes and case discussion.

### The zygomatic implant critical zone

The knowledge and familiarity of the surgeon with anatomic characteristics of the structures that the oblique plane of the planned osteotomy intersects are of utmost importance. Therefore, it is relevant to study in more detail the implant trajectory in several zones of the osteotomy. For didactic purposes, we suggest distinguishing 3 main zones on the zygomatic implant trajectory:

- the “Zygomatic Implant Critical Zone”
- the “Antrostomy Zone”
- the “Anchor Zone.”

Preventing late complications will be closely related to the understanding of the physiology, and function(s) of each of the 3 zones.

The authors of this article propose the name of “Zygomatic Implant Critical Zone” (ZICZ) to define the complex formed by maxillary bone, soft tissue, and the zygoma implant at the coronal level where the first contact with maxillary bone occurs (Figs. 3 and 4). The essentials for the localization of the ZICZ and implant osteotomy/trajectory can be found in the ZAGA Concept and will be discussed in a more detailed manner in a specific chapter. Residual alveolar bone and soft tissue preservation at the coronal level of the zygomatic implant are critical to prevent oral-sinus or oral-nasal fistula and soft tissue dehiscence, which are the most common late complications (Figs. 5–25). Bone and soft tissue maintenance at the ZICZ should be one of the main goals of our surgical procedure.<sup>4–6</sup> In this regard, a series of protocols, tools, interventions, and procedures are proposed to reach appropriate bone and soft tissue stability on the ZICZ (Table 1).

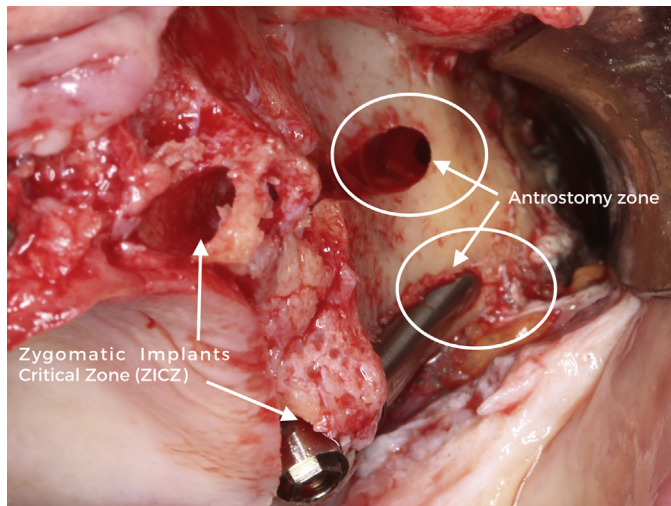
*The antrostomy zone* is the area where the drill penetrates into the maxillary sinus cavity (see Fig. 3; Fig. 26). The recommended ZAGA minimally invasive osteotomy procedure matches the implant shape by direct bone drilling in the 3 zones. No previous “window” or “slot” osteotomy is performed nor required. Depending on the maxillary anatomy, *the antrostomy zone* will be located more or less apically from the ZICZ. As a rule of thumb, the antrostomy should be located as far as possible from the ZICZ. Excluding ZAGA types 0 and 1 that are perforating the sinus floor, the *antrostomy zone* is usually located at the zygomatic process of the maxilla, below the zygomaticomaxillary suture. To determine the ZICZ position, anatomic, numerical, and implant design tridimensional criteria are used. To avoid fracture of the zygomatic bone during or after the drilling procedure, a minimum amount of 3 mm of bone thickness should be left on top of the implant at the zygoma level. Accordingly, the location of the antrostomy will depend on the zygoma buttress curvature and the position of the coronal entrance point. The flatter the zygomatic buttress, the more inferior the antrostomy perforation should be. On the contrary, the more pronounced the buttress curvature is the higher the entrance (Figs. 27–54).

*The Anchoring Zone* is the section of the zygomatic bone where the implant reaches its maximal primary stability (see Fig. 3; Fig. 55). As zygomatic bone consists of trabecular bone with unfavorable features for implant placement, structural

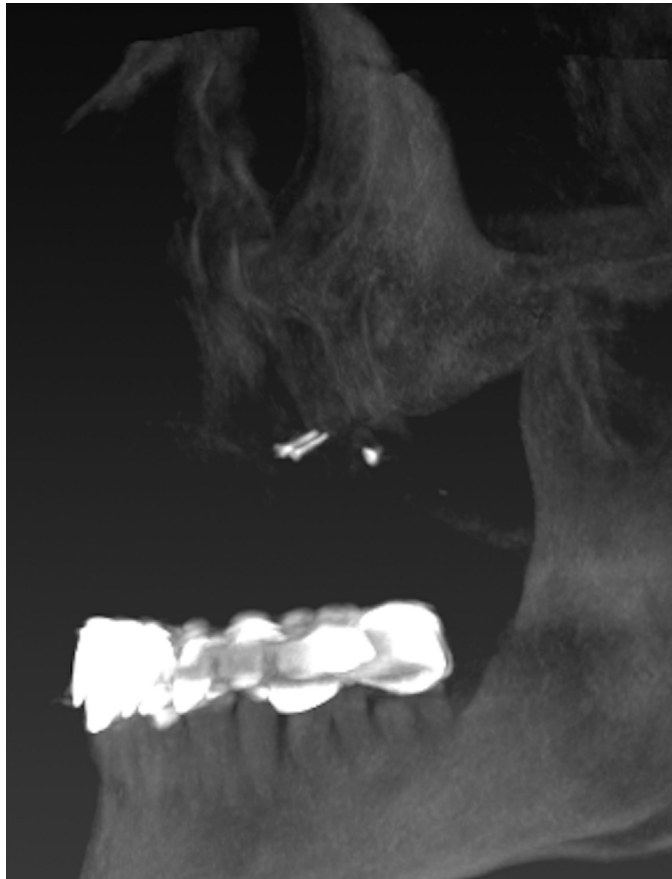
**Table 1** ZAGA Concept recommended procedures to achieve and maintain bone and appropriate soft tissue stability on the Zygomatic Implant Critical Zone (ZICZ)

1	<i>Postpone the intervention until soft tissue is totally healed</i>
2	Use a <i>palatal incision</i> , displacing and augmenting connective tissue buccally to the implant platform
3	Perform an adequate <i>minimally invasive osteotomy</i> procedure according to the ZAGA Concept
4	Use an <i>implant section and design</i> matching the osteotomy
5	Consider using adequate <i>abutment height</i> , and positioning the implant-abutment junction as far as possible from the ZICZ to maintain the bone marginal level. The latter is of special relevance if a straight 0° implant head design is used.
6	Use a <i>final abutment</i> from the beginning
7	Use the <i>Buccal Fat Pad</i> , the <i>ZAGA Scarf Graft</i> , or other soft tissue regenerative procedures if dehiscence is foreseen. A Scarf Graft is a pediculated connective tissue graft around the neck of the implant, with the goal of increasing the amount of buccal tissue.
8	<i>Suturing</i> considerations for obtaining a primary closure
9	Recommend adequate <i>hygiene</i> and <i>diagnostic procedures</i> to avoid jeopardizing the hemidesmosomal junction between titanium and soft tissue.
10	Avoid ZI micromotion under masticatory load using a <i>rigid framework</i>





**Fig. 26** Antrostomy zone. The figure shows the spot where the antrum is perforated. Namely the antrostomy zone.



**Fig. 27** Case 2 - 0- MC- profile pre\*. As a medical history resume, this patient underwent two failed full mouth implant rehabilitations including BGR procedures also failed. The radiological profile shows the unfavorable biomechanical situation of the patient at the first visit. Very closed Goniac angles (powerful masseter muscles); maxillary atrophy and natural dentition on the lower jaw are risk factors for mechanical complications. The extreme maxillary atrophy is a risk factor for biological late complications such as fistula and soft tissue incompetence.

zygomatic stabilization will be maximized when 4 cortices of the maxillary zygomatic process and zygomatic bone are penetrated.<sup>7</sup> The latter is sometimes achieved by the insertion of the implants through the fossa infratemporalis. The ZAGA Concept implies the use of a more tangential zygomatic bone-to-implant contact in the most atrophic anatomies. Obviously, the use of narrow-diameter implants/drills helps to preserve the zygomatic structure.

## Preoperative evaluation

### Health status evaluation and oral considerations

The systemic health status of the patient must be evaluated. Using the American Society of Anesthesiologists (ASA) classification is highly recommended. Relevant aspects related to zygomatic implant surgery are:

- Use of bisphosphonates
- History of local irradiation
- History of diabetes
- Smoking
- Patient psychology and expectations
- Oral hygiene and periodontal risk assessment
- Need for tooth extraction
- Oral mucosa status
- Antagonist dentition type and extension
- Acute or chronic sinusitis
- Maxillary or zygoma pathology
- Mouth opening

### Prosthetic and biomechanical evaluation

A comprehensive evaluation of the edentulous maxilla includes accurate pretreatment assessment of related prosthetic factors, which include the following:

#### Smile line/visibility of the residual crest

The visibility of the transition line between soft tissue and prosthetic reconstruction may occur either anteriorly or posteriorly associated with alveolar resorption in zones I and II and sinus pneumatization. Selecting an intrasinus zygomatic implant path, if prosthetic components are foreseen to be visible, maybe an option to evaluate if a reduction of the alveolar height cannot be performed.

#### Biomechanical status

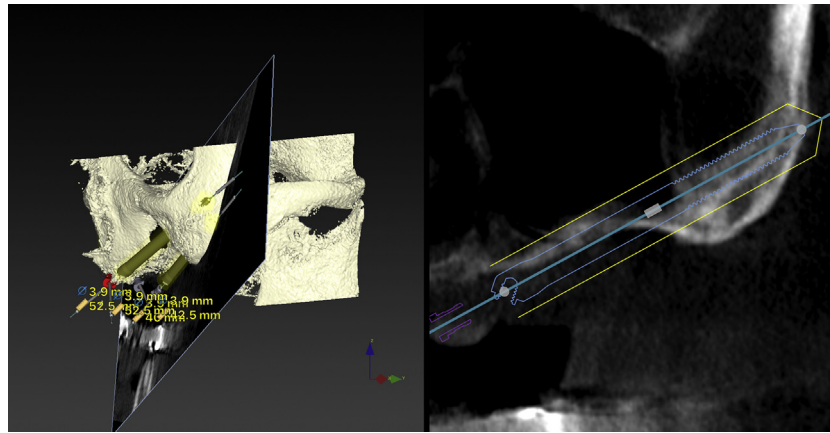
Analysis of the skeletal relationship between the 2 jaws with emphasis on the anterior offset must be performed (Fig. 56, see Figs. 27–54). Also, parafunctional habits shall be evaluated.

## Radiologic evaluation

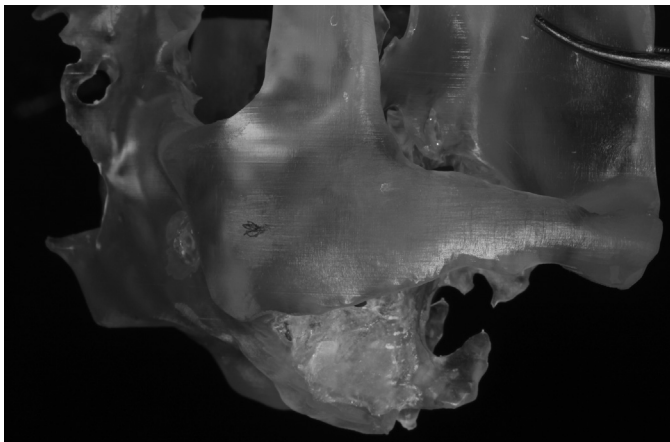
### Methods for radiological assessment

The methods best suited in the assessments are computed tomography (CT) and cone-beam CT (CBCT). Conventional motion tomography can be used but does not offer the same image clarity as CT or CBCT and requires a higher radiation dose. A checklist of the surgical information to be gathered before diagnosis is listed in Box 1.

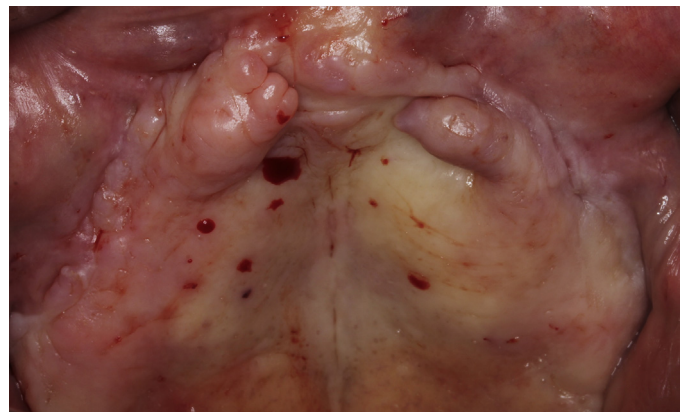




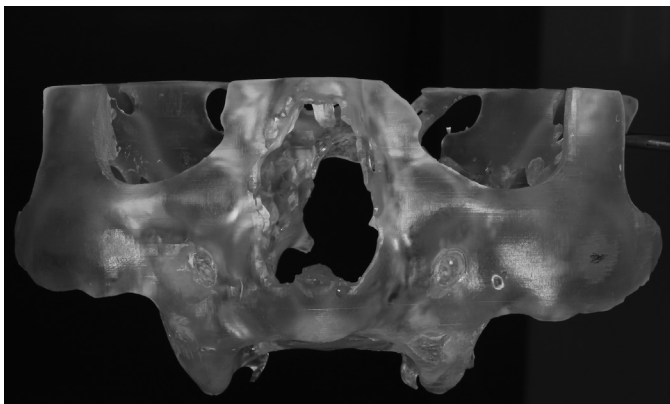
**Fig. 31** Case 2 - 4- MC-UL 25 virtual. The “flat” palate together with alveolar incompetence are reasons to externally move the implant path.



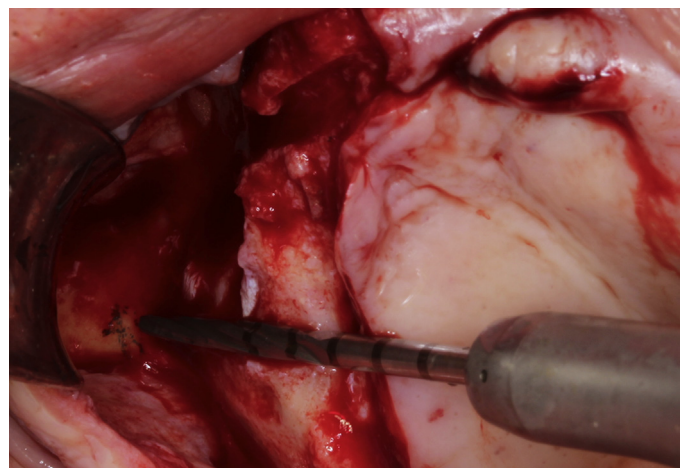
**Fig. 32** Case 2 - 5- MC-3-D model profile. A 3-D model printed at [ct@zagacenters.com](http://ct@zagacenters.com) is routinely used for surgery rehearsal.



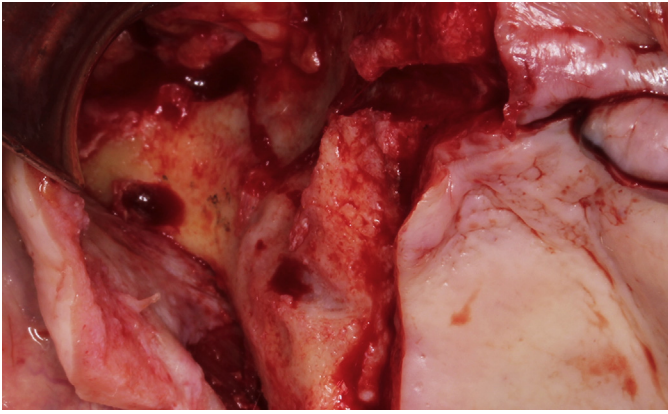
**Fig. 34** Case 2 - 7- MC-Occlusal soft tissues-pre. Soft tissue after failed multiple implants and GBR procedures. Surgeons must foresee potential late soft tissue complications.



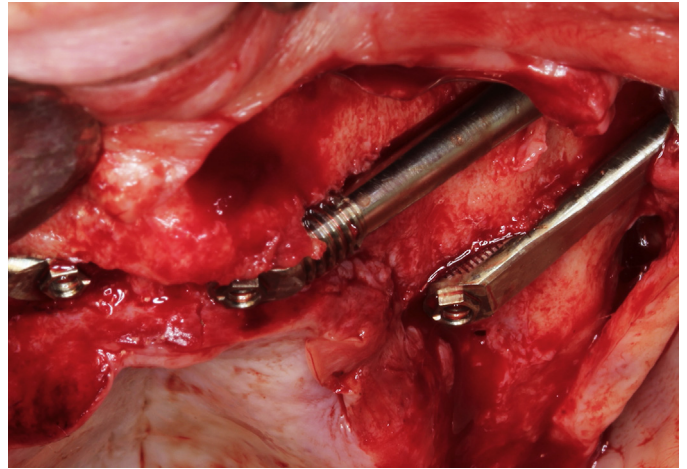
**Fig. 33** Case 2 - 6- MC-3-D model. In addition to the flat palate, the 3-D model shows pneumatized maxillary sinuses.



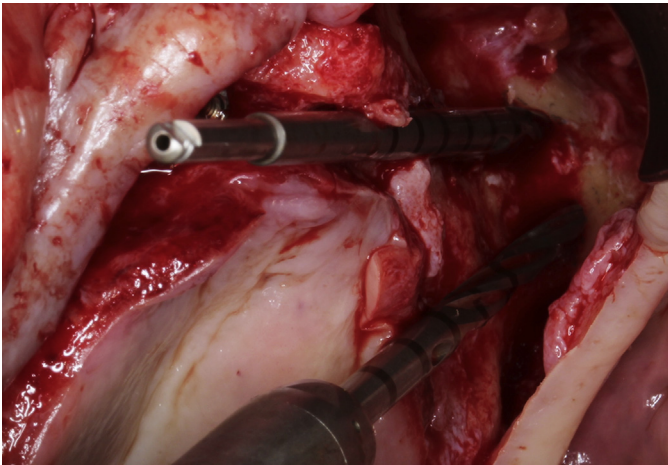
**Fig. 35** Case 2 - 8- MC- Versah lateral osteotomy 15. A Versah zygo-bur is being used to start the osteotomy at the second pre-molar position.



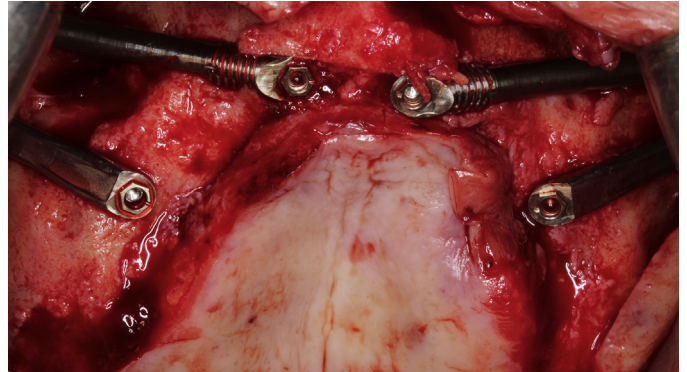
**Fig. 36** Case 2 - 9- MC- osteotomy 15 to 13. Two conservative osteotomies maintaining sinus lining integrity have been performed.



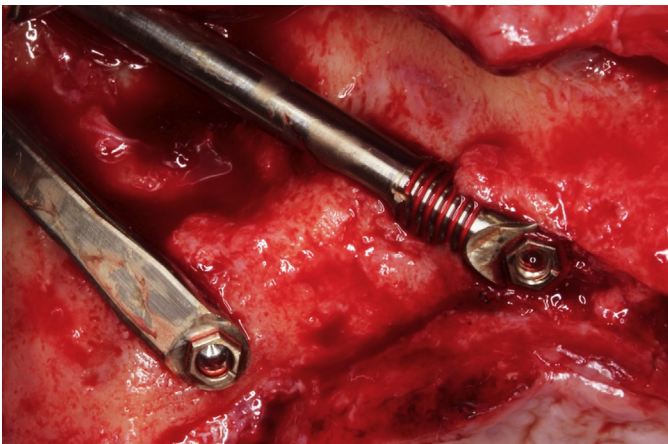
**Fig. 39** Case 2 - 12- MC- implants 23 to 25. Lateral view ZAGA Flat and Round zygomatic implants, placed at left second premolar and lateral incisor positions. The minimal remains of alveolar bone used for a conservative osteotomy, together with the use of an appropriate implant design minimizes the risk for late complications.



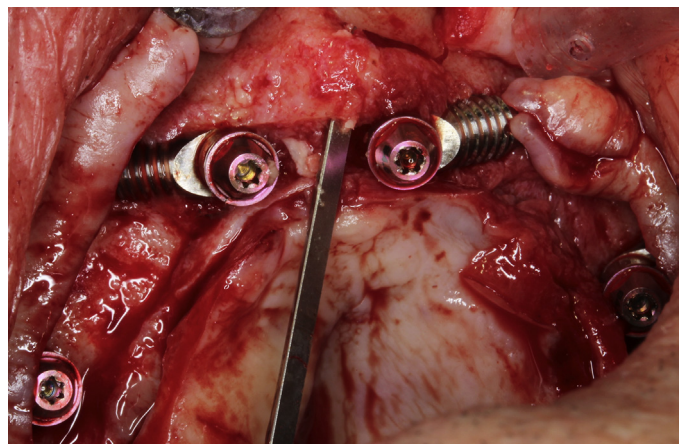
**Fig. 37** Case 2 - 10- MC- osteotomy 25 to 23. While maintaining in place a long Versah zygo-drill as a guide, the distal channel is being carved.



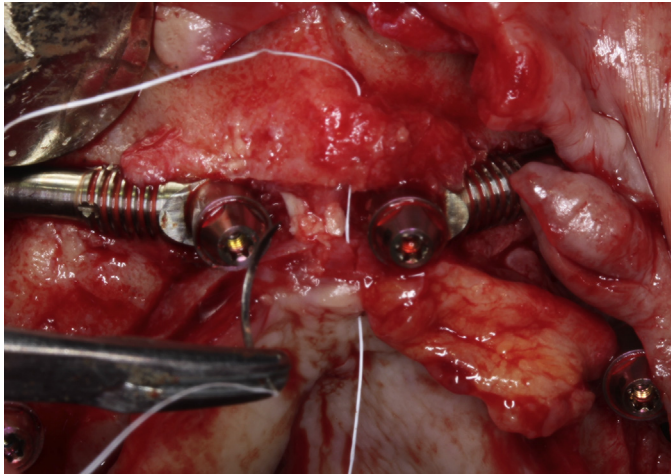
**Fig. 40** Case 2 - 13- MC- occlusal. Occlusal view of the Straumann ZAGA, 3.4 mm diameter zygomatic implants in place.



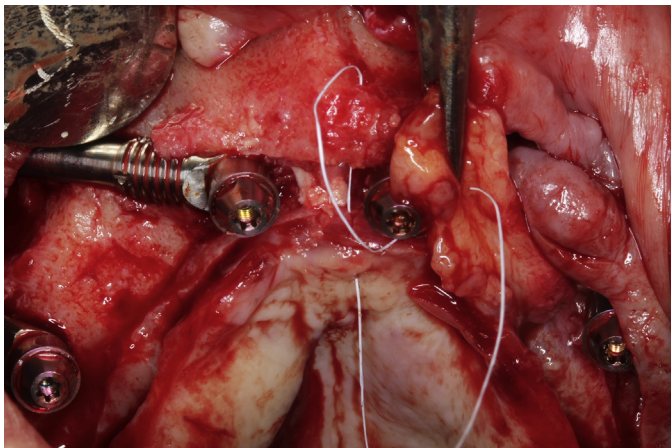
**Fig. 38** Case 2 - 11- MC. Prosthetically driven, adapted to the anatomy, ZAGA Flat, and ZAGA Round zygomatic implants have been anchored on right second premolar and lateral incisor positions.



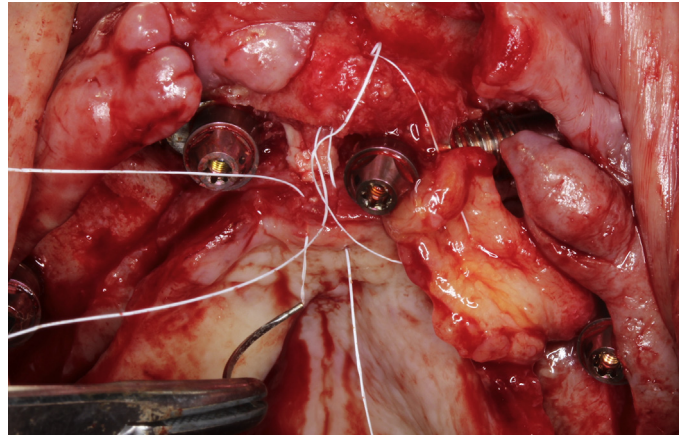
**Fig. 41** Case 2 - 14- MC- ZAGA Scarf graft.<sup>1</sup> Owing to the jeopardized oral mucosa status previous to the surgery eventual soft tissue incompetence was foreseen. Therefore, a ZAGA Scarf Graft procedure was started by creating a suture bony anchorage.



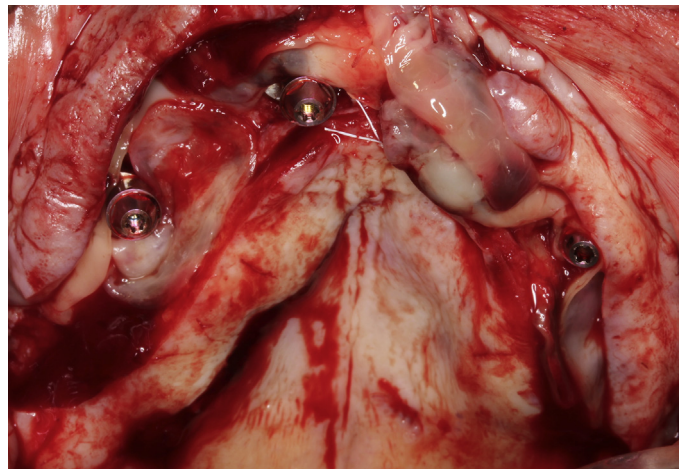
**Fig. 42** Case 2 - 15- MC- ZAGA Scarf graft.<sup>2</sup> A pediculated connective tissue graft has been obtained. Suture starts from the epithelial palatal side, goes through the bony tunnel.



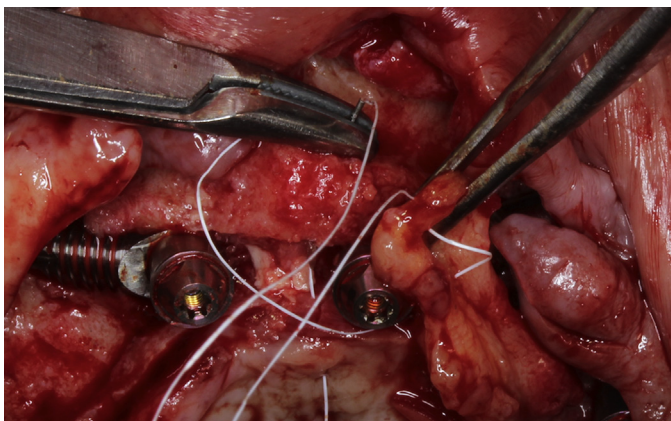
**Fig. 43** Case 2 - 16- MC- ZAGA Scarf graft.<sup>3</sup> The nonresorbable suture perforates the graft from down up and up to down on its way to the buccal side of the bony tunnel.



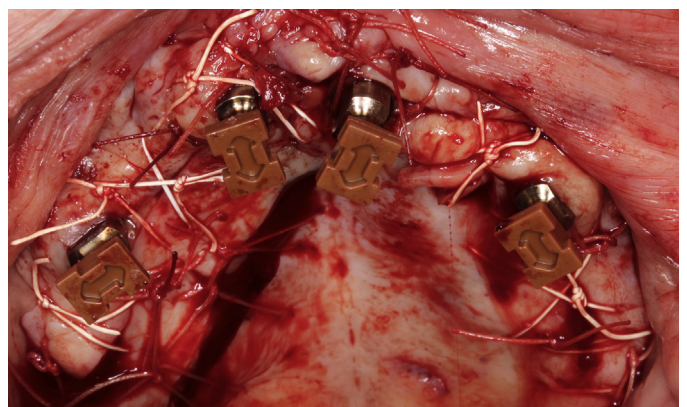
**Fig. 45** Case 2 - 18- MC- ZAGA Scarf graft.<sup>5</sup> The suture knot will be performed at the palatal side.



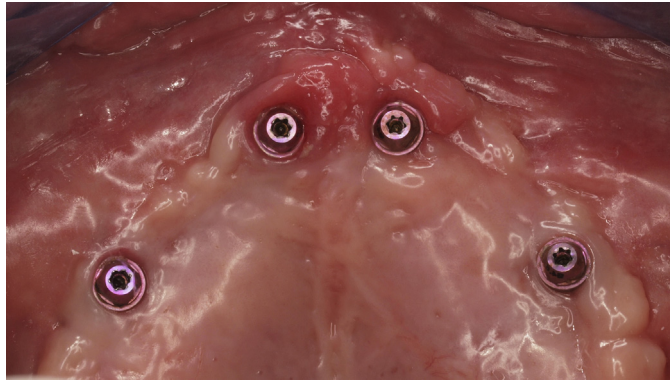
**Fig. 46** Case 2 - 19- MC- ZAGA Scarf graft.<sup>6</sup> Previous suturing, the wound was covered with several L-PRF membranes.



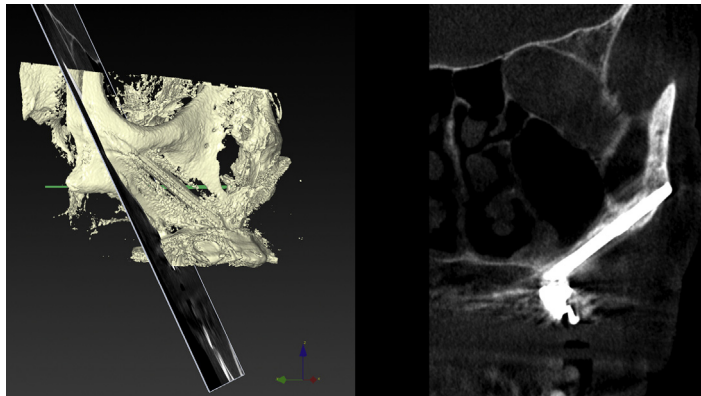
**Fig. 44** Case 2 - 17- MC- ZAGA Scarf graft.<sup>4</sup> After traversing the bony tunnel, the Gore-Tex suture will perforate palatal connective for epithelial emergence.



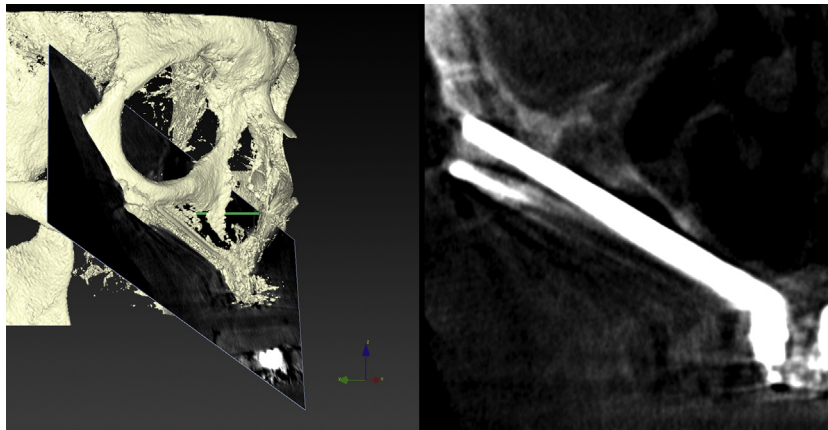
**Fig. 47** Case 2 - 20- MC- suture and impressions. A double pediculated split flap was used for the primary closure of the right side. Straumann impressions pick up caps are in place.



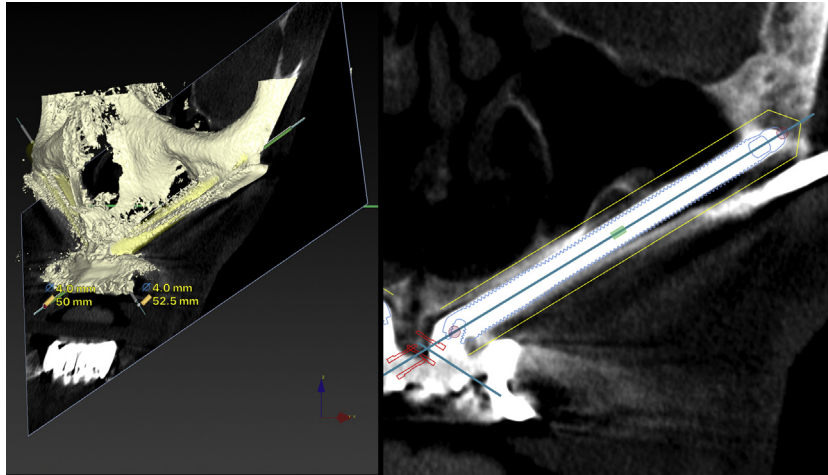
**Fig. 48** Case 2 - 21- MC- 6 months later. Gingival status 6 months later at the moment of final prostheses installation.



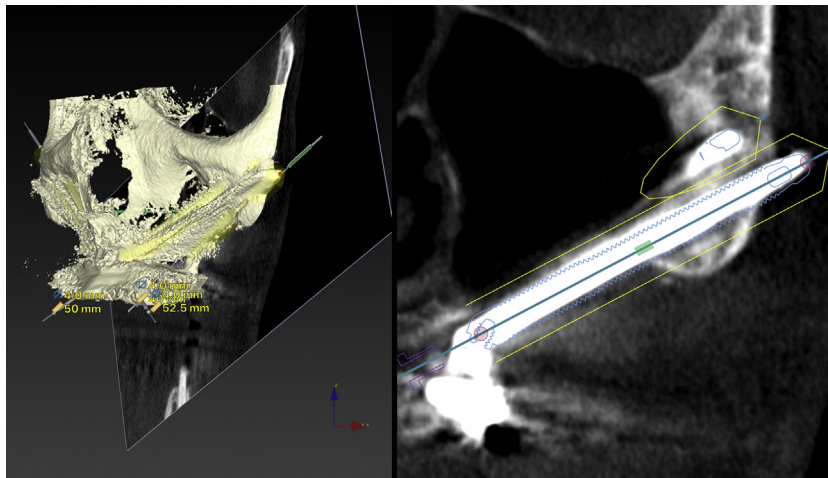
**Fig. 49** Case 2 - 22- MC- 15 to 6 months later. Status of the right posterior implant and maxillary sinus 6 months after surgery. To be compared with [Fig. 28](#).



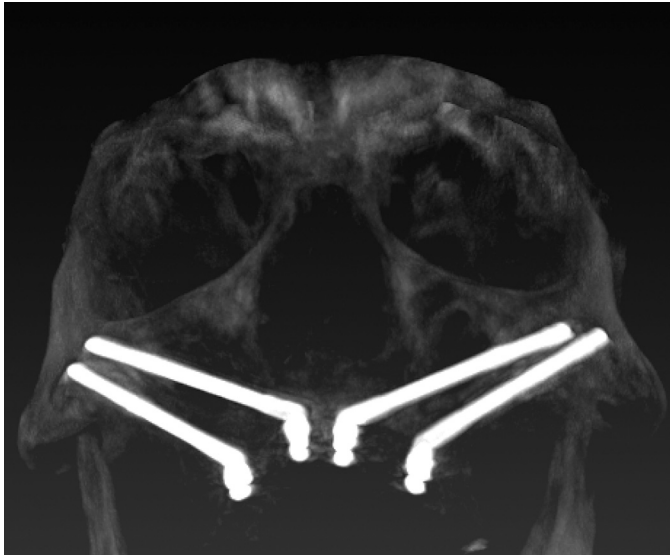
**Fig. 50** Case 2 - 23- MC- 13 to 6 months later. Perfect sinus status at the anterior implant level. To be compared with [Fig. 29](#).



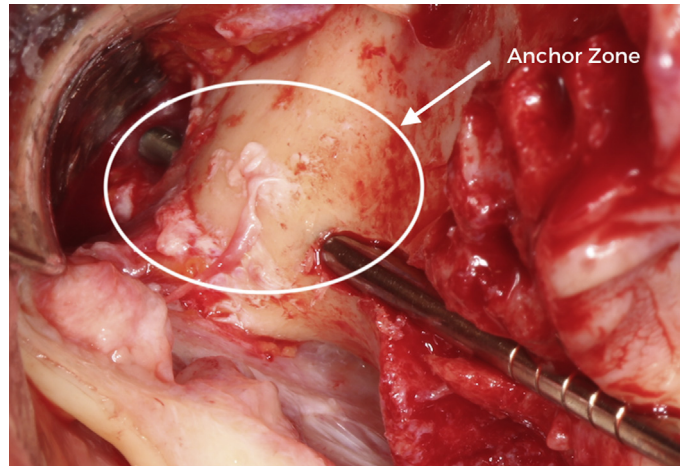
**Fig. 51** Case 2 - 24- MC- 23 to 6 months later. Perfect sinus status at the anterior implant level. To be compared with [Fig. 30](#).



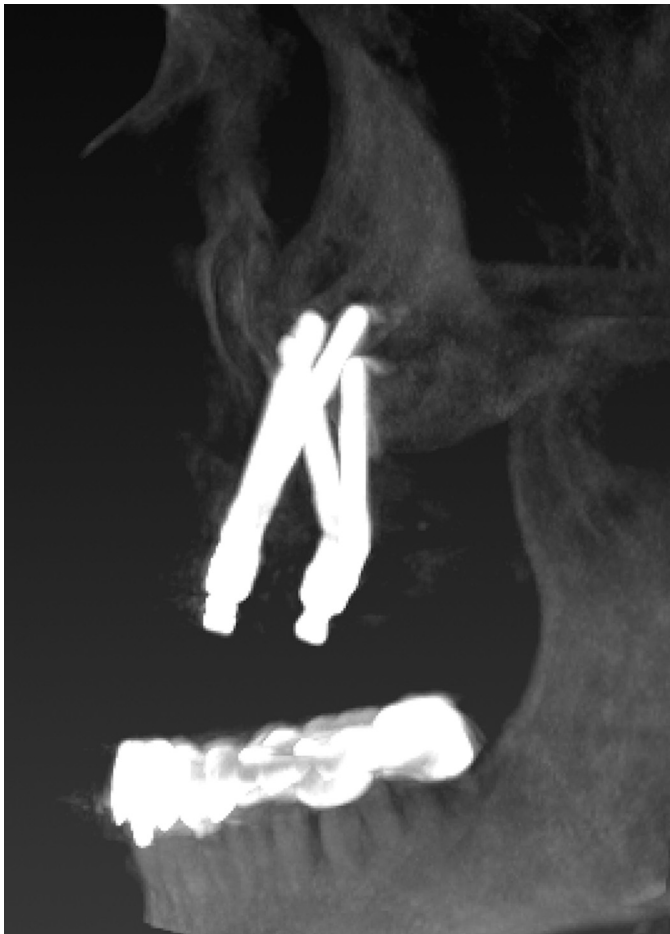**Fig. 52** Case 2 - 25- MC- 25 to 6 months later. Totally transparent maxillary sinus and right posterior implant after 6 months of surgery. To be compared with [Fig. 30](#).



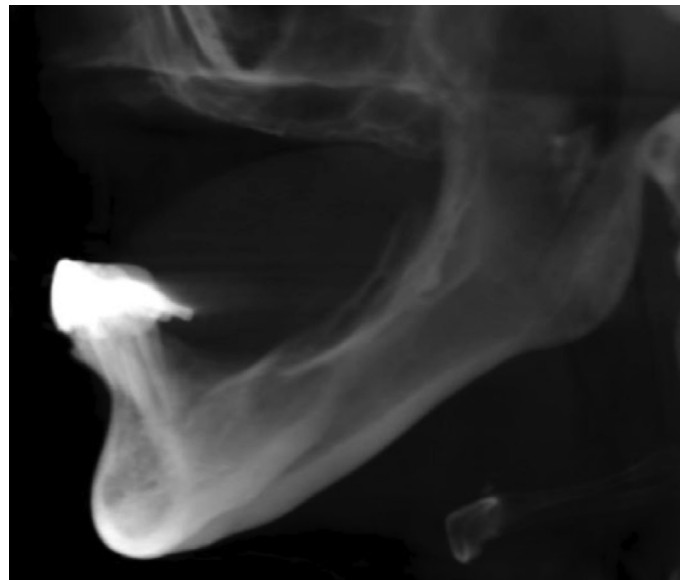
**Fig. 53** Case 2 - 26- MC-post. Anterior-Posterior implant head distribution.



**Fig. 55** Anchor zone. The main anchoring power of the zygomatic fixture is attained by the thorough perforation of the zygomatic bone.



**Fig. 54** Case 2 - 27- MC-profile post. Sagittal cantilever partial correction was obtained by adequate anterior implant positioning. The patient was asked to use premolar areas and a "moderate" masticatory load.



**Fig. 56** Atrophic maxilla profile. The lateral view is showing a biomechanically compromised situation. The extraction of the remaining anterior mandibular teeth and implant placement between foramina for a better load distribution should be considered.



### Box 1. Checklist for radiological evaluation

- Dimensions and quality of the zygomatic bone
- Maxillary lateral wall curvature
- Residual alveolar process architecture and dimensions
- Maxillary sinus condition and osteomeatal unit permeability
- Anatomic variations assessments: vascular anastomosis in lateral sinus membrane, sinus septum, residual alveolar ridge relationship to the palatal artery and foramen
- Skeletal relationship
- Presence or absence of remaining teeth and basic information about them
- Lower jaw dentition type and distribution, if any.

### Alternatives for treatment modality based on the presence of radiologically available bone on different zones

The indication for a rehabilitation anchored on zygomatic implants is the presence of severe maxillary atrophy or resection preventing conventional implant insertion. Depending on the defect extension and intensity on the different maxillary zones (Fig. 57), alternative types of treatment may be considered (Table 2).

### Planning software

Based on 3D x-ray exploration, several planning software options have been developed to facilitate zygomatic implant planning. Residual alveolar bone characteristics along with the curvature of the zygomatic bone are of utmost importance in decision making for defining the zygomatic implant critical zone and antrostomy zone. Optimal osteotomy will be patient-specific and may adopt any path from the intrasinus to the extrasinus.

### Morphometric evaluation and presurgery planning

Current radiological information as DICOM images may easily be transferred and subsequently transformed into an STL

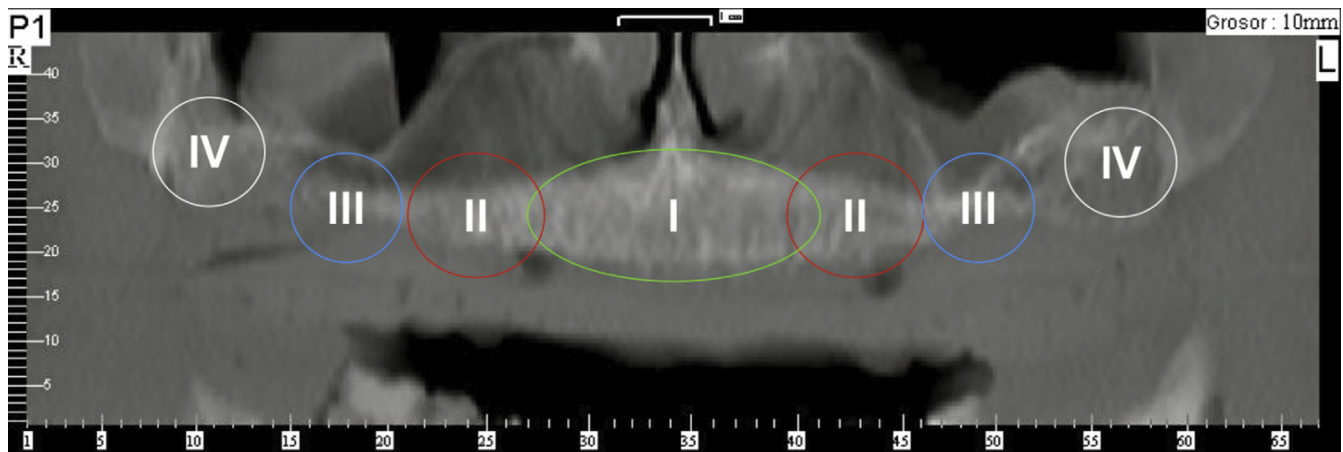


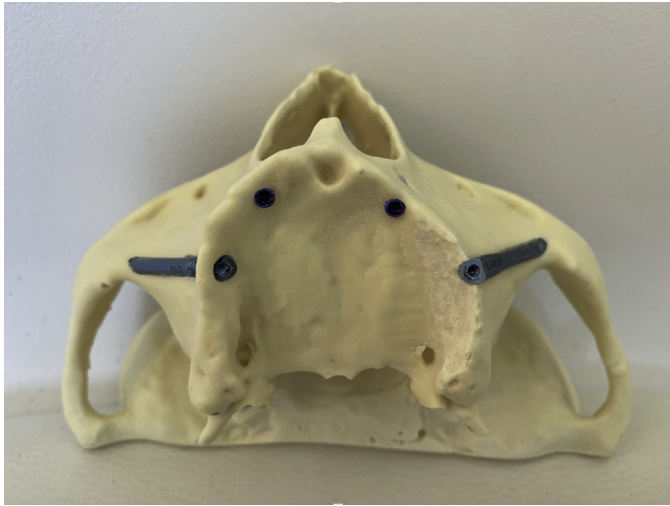
Fig. 57 Maxilla zones. Radiological zones of the maxilla.

Table 2 Radiological guidelines for treatment type and surgical approach

Zone	Bone Presence		
	>10 mm Height and 5 mm Wide	Moderate Atrophy	Severe Atrophy
I: Cuspid-Cuspid	Conventional implant	Zygoma implants	Zygoma implant
II: Premolar	Conventional/Tilted implant	Sinus lift	
III: Molar	Conventional implant	GBR	
IV: Tuberosity	Pterygoid implant		Pterygoid implant

Beyond surgical alternatives, surgeons should consider other variables such as predictive outcome results or minimally invasive techniques for an optimal approach.

*Modified from* Bedrossian E, Sullivan RM, Fortin Y, Malo P, Indresano T. Fixed-prosthetic implant restoration of the edentulous maxilla: a systematic pretreatment evaluation method. *J Oral Maxillofac Surg.* 2008 Jan;66(1):112-22; with permission.



**Figs. 58** 3-D training model. An occlusal view of a 3-D model with two BLX dummy implants (Straumann AG) placed in the anterior and two different designs of zygomatic implants on the posterior maxilla (Straumann ZAGA Round on the right and Straumann ZAGA Flat on the left). The 3-D model was ordered to print by sending the DICOM images to [ct@zagacenters.com](mailto:ct@zagacenters.com)

file format able to be printed using three-dimensional stereolithographic technology (Fig. 58). Constructed from digital image data, 3D models will facilitate the surgeon familiarizing with the internal and external anatomy of the patient's maxilla. In the experience of the authors, using 3D models with advanced maxillary atrophies is extremely helpful.

### Legal aspects considerations

The informed consent of all procedures must be gained from the patient before all surgical procedures. Also, pre-clinical evaluation documents such as intraoral and facial pictures, 3D models or radiographic explorations have a legal value to prove professional competence. Finally, complications are frequently associated with deficient treatment planning.

### Clinics care points

- This treatment should be performed knowing one's own limitations and eventually seeking consultation whenever appropriate.
- A zygomatic implant may adopt different trajectories.
- For didactic purposes, we suggest distinguishing 3 main zones on the zygomatic implant trajectory.
- Bone and soft tissue maintenance at the ZICZ should be one of the main goals of our surgical procedure.
- Constructed from digital image data, 3D models will facilitate the surgeon familiarizing with the internal and external anatomy of the patient maxilla.

### Acknowledgments

Straumann AG generously donated most of the implants shown on the pictures, while Versah.com kindly donated the Zyg-Osseococondensation drills; however described ZAGA protocols properties belong to the authors, and Straumann and Versah by no means interfered with this publication concepts.

### References

1. Brånemark PI, Gröndahl K, Ohnell LO, et al. Zygoma fixture in the management of advanced atrophy of the maxilla: technique and long-term results. *Scand J Plast Reconstr Surg Hand Surg* 2004;38:70–85.
2. Aparicio C, editor. *Zygomatic implants: the anatomy-guided approach*. 1st edition. United Kingdom: Quintessence Pub Co; 2012.
3. Aparicio C. A proposed classification for zygomatic implant patients based on the zygoma anatomy-guided approach (ZAGA): a cross-sectional survey. *Eur J Oral Implantol* 2011;4:269–75.
4. Aparicio C, López-Piriz R, Albrektsson T. ORIS criteria of success for the zygoma related rehabilitation: the (revisited) zygoma success code. *Int J Oral Maxillofac Implants* 2020;35:366–78.
5. Aparicio C, Antonio S. Zygoma anatomy-guided approach "scarf graft" for prevention of soft tissue dehiscence around zygomatic implants: technical note. *Int J Oral Maxillofac Implants* 2020;35:e21–6.
6. De Moraes EJ. The buccal fat pad flap: an option to prevent and treat complications regarding complex zygomatic implant surgery. Preliminary report. *Int J Oral Maxillofac Implants* 2012;27(4): 905–10.
7. Nkenke E, Hahn M, Lell M, et al. Anatomic site evaluation of the zygomatic bone for dental implant placement. *Clin Oral Implants Res* 2003;14:72–9.