


RESEARCH ARTICLE

Open Access



Effect of osseodensification on the increase in ridge thickness and the prevention of buccal peri-implant defects: an in vitro randomized split mouth pilot study

Fausto Frizzera^{1*} , Rubens Spin-Neto², Victor Padilha³, Nicolas Nicchio⁴, Bruna Ghiraldini⁵, Fábio Bezerra⁶ and Elcio Marcantonio Jr⁴

Abstract

Background: Implant installation with conventional drilling can create buccal bone defects in areas of limited ridge thickness. Implant installation with osseodensification may aid in preventing buccal bone defects in these situations. This in vitro pilot study evaluated the impact of osseodensification on the increase in alveolar ridge thickness and the prevention of buccal peri-implant defects.

Methods: Ten fresh pig mandibles with limited bone thickness were selected for use in an experimental randomized split mouth pilot study. Two site-preparation protocols were used: conventional drilling with cutting burs (CTL, n = 10) and osseodensification with Densah[®] burs (OD, n = 10). After implant bed preparation, 20 implants (4.5 × 10 mm) were placed in the prepared sites and the insertion torque was recorded. Clinical and photographic analysis evaluated ridge thickness and the extent (height, width, and area) of bone defects in the buccal and lingual bone walls following implant placement. Three-dimensional measurements were performed using STL files to analyze the increase in buccal ridge thickness following site preparation and implant placement. The height of the buccal bone defect was considered as the primary outcome of this study. Defect width, area, implant insertion torque, and linear buccal ridge increase after implant site preparation and installation were also assessed. Non-parametric evaluations were carried out with the Mann–Whitney test to verify intergroup differences.

Results: There was no statistically significant difference between groups in the baseline ridge thickness. OD presented a significantly higher insertion torque, associated with reduced buccal and lingual bone defect width, in comparison to CTL.

Conclusions: The increase in buccal ridge thickness after site preparation and implant placement was significantly higher in OD compared to CTL. Osseodensification increased the ridge thickness through expansion and reduced buccal bone defects after implant installation.

Keywords: Osseodensification, Bone augmentation, Prevention, Dental implants, Alveolar ridge expansion

Background

Dental implants are a reliable and well-documented solution for replacing missing teeth. Patients prefer implant-supported restorations that are similar to their natural dentition. This preference has increased the complexity

*Correspondence: faustofrizzera@yahoo.com.br

¹ FAESA University Center, Vitória, Brazil

Full list of author information is available at the end of the article



© The Author(s) 2022. **Open Access** This article is licensed under a Creative Commons Attribution 4.0 International License, which permits use, sharing, adaptation, distribution and reproduction in any medium or format, as long as you give appropriate credit to the original author(s) and the source, provide a link to the Creative Commons licence, and indicate if changes were made. The images or other third party material in this article are included in the article's Creative Commons licence, unless indicated otherwise in a credit line to the material. If material is not included in the article's Creative Commons licence and your intended use is not permitted by statutory regulation or exceeds the permitted use, you will need to obtain permission directly from the copyright holder. To view a copy of this licence, visit <http://creativecommons.org/licenses/by/4.0/>. The Creative Commons Public Domain Dedication waiver (<http://creativecommons.org/publicdomain/zero/1.0/>) applies to the data made available in this article, unless otherwise stated in a credit line to the data.

of implant treatment, making it necessary to reestablish the harmony between the prosthetic crowns and the surrounding hard and soft tissues. To achieve an adequate esthetic and functional outcome, the implant must be installed in the correct tridimensional position, an action that often requires additional bone preservation and/or reconstruction procedures [1, 2].

The alveolar process is remodeled after tooth extraction and promotes changes in the shape of the ridge, which can complicate or preclude implant installation without previous bone grafting [3]. Bone grafts have been extensively used to provide sufficient anchorage prior to implant placement [4] or to correct small peri-implant defects at the time of implant installation [5, 6]. Although documented as having good predictability, bone grafting increases the cost and time of treatment, surgical morbidity, and consumption of postoperative medications while decreasing patient acceptance [7].

Evaluating the results of a therapy considering patient-centered outcomes, along with the clinical and biological rationale, enable less invasive procedures with reduced treatment time [8]. Surgical and prosthetic techniques that promote an increase in hard and soft tissue quantity and quality are interesting options to guarantee more favorable results for patients [9].

The osseodensification protocol, initially proposed by Huwais [10, 13], represents a paradigm shift in the preparation of bone tissue prior to implant placement. It has shown promising results in the osseointegration process [11], enabling to increase the bone density at the prepared implant site [12, 13], avoiding more invasive techniques to elevate the maxillary sinus membrane [14], and increasing the volume of the ridge [15], preventing the occurrence of peri-implant bone defects.

The current protocol for the preparation of the implant site consists of using cutting drills at high speed and with clockwise rotation under constant irrigation to remove the bone tissue and install the implant in the desired region [16]. Osseodensification uses non-cutting drills in counter clockwise rotation to prepare the site to receive an implant. The prepared bone fragments are reintroduced to the site's lateral trabecular bone walls, compacting and increasing the density of the bone instead of removing the bone as performed in conventional drilling. Biologically, osseodensification provides greater bone-to-implant contact and increases the removal torque of implants, besides reducing the time required for osseointegration [11, 12, 15, 17]. From the clinical point of view, osseodensification promotes greater primary stability [18]. The implants installed using this technique can also have a larger diameter, when compared to the conventional technique of osteotomy using cutting drills, and can increase the volume of the bone crest [15]. Tretto

et al. (2019) [19] carried out a systematic review of the literature on the techniques used to prepare the bone to receive an implant and stated that osseodensification has shown promising and encouraging biomechanical results. In recent years several publications have assessed this procedure [20–24] but the occurrence and extent of peri-implant defects in the mandible have rarely been addressed. Therefore, the aim of this in vitro pilot study was to evaluate the impact of osseodensification on the increase in ridge thickness and the prevention of buccal peri-implant defects. The hypothesis was that osseodensification would expand the ridge and compress the cancellous bone around the implant site without causing major bone defects.

Methods

Animals

This study was approved by the Animal Ethics Committee of the Araraquara Dental School FOAr—Unesp under protocol 20/2019. Ten animals that were approximately one year old with an average weight of 100 kg and edentulous space on the jaw greater than or equal to 10 mm between the lower canine and first lower premolars were selected. The Suimartin slaughterhouse (Viana, Espírito Santo, Brazil) sacrificed the pigs to market the pork meat and provided the jaws to be used in this study. After the study the slaughterhouse disposed the mandibles in accordance with health regulations.

Study design

After transporting the jaws to the study site, a crestal incision was performed bilaterally in the edentulous region between the lower canine and the lower first premolar. At both proximal extremities vertical buccal incisions were created to facilitate access to and visualization of the area of interest. A full thickness flap exposed the bone tissue and was extended 15 mm vertically. The mandible was fixed in a device to standardize its position and bone scanning was performed with an intraoral scanner (Trios3 mono—3Shape, Copenhagen, Denmark) at the resolution determined by the manufacturer. A gauge ruler was fitted on the ridge and a digital caliper (Mitutoyo, Suzano, Brazil) was used to measure the thickness of the ridge 1 mm below the crest.

The ridge received two types of site preparation: 1—conventional with standard cutting burs (CTL group) or 2—modified by osseodensification with the Densah® burs (Densah Burs, Versah, Jackson, USA) (OD group). This was a split-mouth study, thus software (Randomizer for clinical trials, Regis Bournique) was used for randomization to determine the first side to be operated and to choose which area to receive the perforation with the cutting drills or osseodensification.

An electric motor and hand-piece (NSK, Tokyo, Japan) were used to prepare the sites to receive cone morse implants (4.5×10 mm CM SW Plus; S.I.N. Implant System, Sao Paulo, Brazil). In the CTL group an initial guide drill, a twist drill 2.0 and tapered burs measuring 3.0, 3.3 and 4.0 mm (S.I.N. Implant System, Sao Paulo, Brazil) were used to prepare the site perpendicularly to the ridge with the following settings: clockwise rotation at 800 RPM and 20 Ncm torque. In the OD group the pilot and osseodensification burs 2.0, 2.3, 3.0, 3.3 and 4.3 Den-sah® burs were used with counterclockwise rotation at 800 RPM and 20 Ncm of torque. Copious irrigation was performed to prevent bone heating while assisting in the process of cutting or densifying. The perforation depth was established at 11 mm since the implant had to be installed 1 mm below the crestal level as recommended by the manufacturer's guidelines. The mandible was reattached to the positioning device and the digital scan was repeated to evaluate the alteration in the ridge thickness.

The implants were placed in position initially with a hand-piece operating at 20 RPM until it reached 35 Ncm torque or the crestal level. A manual torque wrench (S.I.N. Implant System, Sao Paulo, Brazil) was used to finish implant placement and to evaluate the final insertion torque. The mandibles were scanned again and the sites were verified to check the occurrence of defects in the bone walls immediately after placement. All surgical procedures were carried out by a single operator.

Analysis of bone volume

The STL files obtained from the digital scan before (T1) and after (T2) perforation, and after implant installation (T3), were imported into software (ExoCAD, Fraunhofer-Gesellschaft, Munich, Germany) that allowed the analysis of the images and any overlap [25]. To standardize the position of every pair of evaluations, an automatic

adjustment was made by the software followed by a manual fine adjustment if necessary, where the first lower premolars were used as the reference. An evaluator, blinded to groups and provided with access only to STL files, performed these measurements twice, with a 7-day interval between the first and second evaluation. The following measurements were performed: (1) T1 (baseline) linear bucco-lingual evaluation of the ridge thickness at the level (0 mm) of the bone crest and 1, 2, 4, 6 mm apically; (2) linear buccal ridge increase after T2 (T1/T2); (3) linear buccal ridge increase after T3 (T2/T3).


Analysis of the presence and extent of bone defect

Initially, the absence of a buccal bone defect was verified after implant installation and a standardized photograph was taken. The camera was positioned on a tripod with an angulation perpendicular to the area of interest and a periodontal probe (PCP-UNC 15, Hu-Friedy, Chicago, USA). In addition, the position, lens magnification and framing of each photograph was standardized using the following equipment: EOS Rebel T5i reflex camera, macro lens (EF 100 mm f / 2.8L IS USM) and circular flash Mr 14ex (Canon inc, Tokyo, Japan); the values of 1/125 for shutter speed, F25 for aperture and ISO 100 were selected.

The number of buccal defects present in each group was counted. Further, the height, width, and area of the defect (Fig. 1) in the buccal and lingual aspect were measured with software (ImageJ)—National Institutes of Health, Bethesda, USA). Measurements in pixels were converted to approximate values in millimeters using the periodontal probe as a reference.

Data evaluation

The height of the buccal bone defect was considered as the primary outcome of this study. Changes in defect



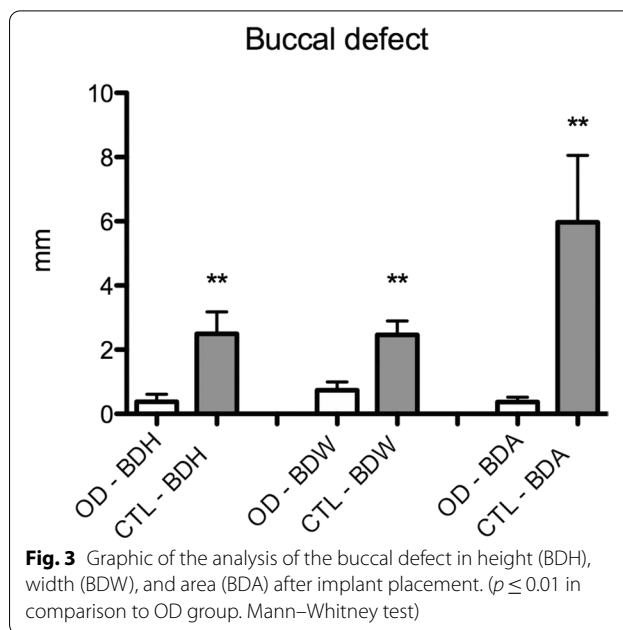
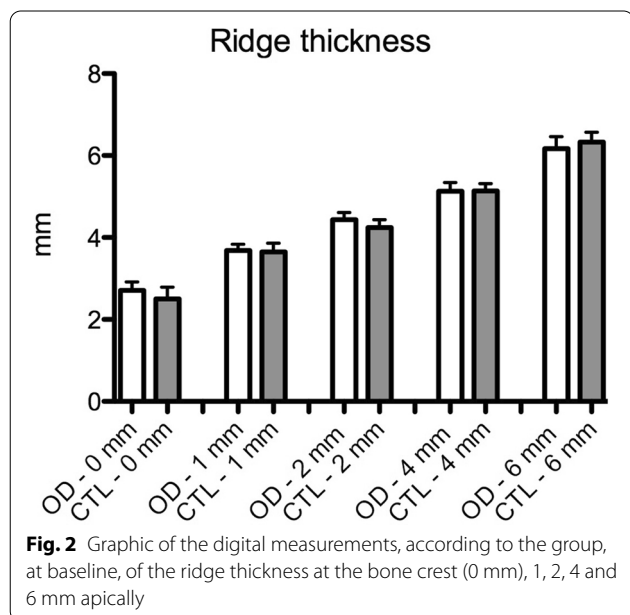
width, area, implant insertion torque, and linear buccal ridge after implant site preparation and installation were also assessed. Non-parametric evaluations were carried out with the Mann–Whitney test to verify intergroup differences. GraphPad Prism 8 software (San Diego, CA, USA) was used to perform statistical analyses. All tests were applied with a significance level of 5% ($p \leq 0.05$). An independent observer was aware of the group allocation at the different stages of the experiment.

Results

Independent of the study group, the operator was able to install all implants as planned, in the desired regions. All sites were included in the study. The implant insertion torque was significantly higher in the OD group ($49.9 \pm 11.45 \text{ N/cm}^2$) compared to the CTL group ($40.4 \pm 8.07 \text{ N/cm}^2$), $p < 0.05$.

There was no significant difference between groups regarding ridge thickness in the evaluated positions, at baseline (Fig. 2). Also, there was no significant difference between the digital and analog analysis of the ridge thickness at this baseline time point.

Osseodensification reduced the occurrence of buccal defects (Fig. 3). In the CTL group, eight buccal bone defects greater than 0.5 mm in height were present, while in the OD group, there was only one. There was a significant difference in comparison to the CTL group in the height (CTL: 2.5 ± 2.14 ; OD: 0.37 ± 0.72), width (CTL: 2.46 ± 1.38 ; OD: 0.73 ± 0.82), and area (CTL: 5.97 ± 6.57 ; OD: 0.36 ± 0.47) of the buccal defect (Fig. 4). In the analysis of the lingual aspect of the bone, there was a significant difference in favor of the OD group in reducing the



width (CTL: 3.17 ± 1.54 ; OD: 1.98 ± 1.10) and area (CTL: 4.65 ± 3.24 ; OD: 1.72 ± 1.06) of the defect in comparison to the CTL group (Fig. 5).

The OD group presented a significant increase in ridge expansion reflected in a higher increase in the buccal bone at the crestal level and 1 mm apically after site preparation (Crestal—CTL: 0.18 ± 0.2 , OD: 0.66 ± 0.64 ; 1 mm—CTL: 0.09 ± 0.15 ; OD: 0.39 ± 0.37) (T1/T2—Fig. 6) and implant placement (Crestal—CTL: 0.03 ± 0.11 , OD: 0.28 ± 0.35 ; 1 mm—CTL: 0.07 ± 0.13 ; OD: 0.25 ± 0.35) (T2/T3—Fig. 7) when compared to the CTL group (Figs. 8 and 9).

Discussion

Osseodensification led to increased ridge thickness and reduced the number and size of peri-implant buccal defects in this in vitro model. This is consistent with the literature, which describes these results as an advantage of osseodensification [15] when used in areas with lower bone density [20]. Increasing the thickness of the bone ridge can reduce morbidity and the number of surgical procedures necessary to properly install an implant in those ridges with compromised bone thickness, which impedes the proper three-dimensional positioning of the implant [1, 2].

The evolution of dental implant procedures has improved patients’ postoperative outcomes and implant survival [26, 27]. In the present study, while osseodensification was able to improve the ridge thickness, it should be acknowledged that its combination with a tapered

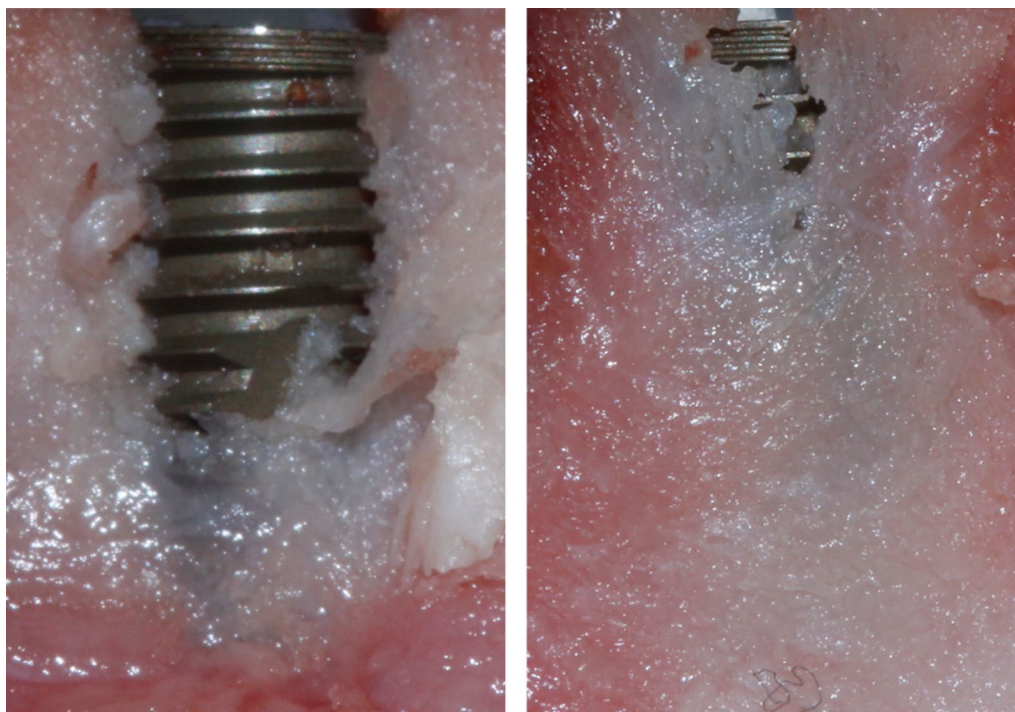

Fig. 4 Clinical images of the worst defects in the buccal aspect of groups CTL (left) and OD (right)

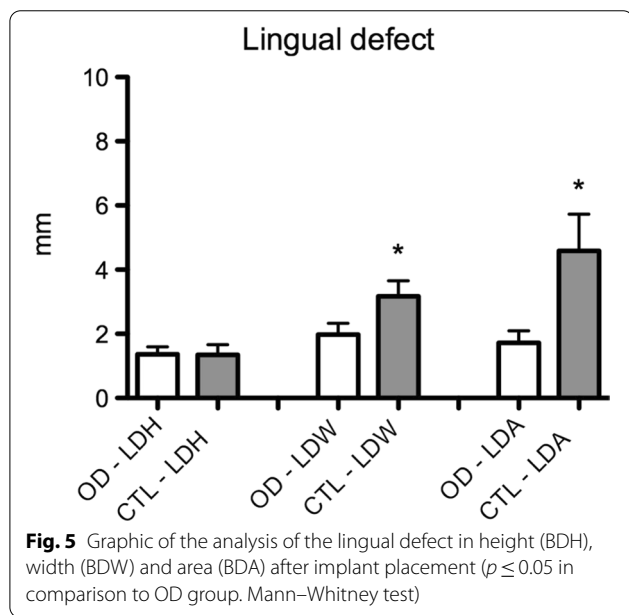


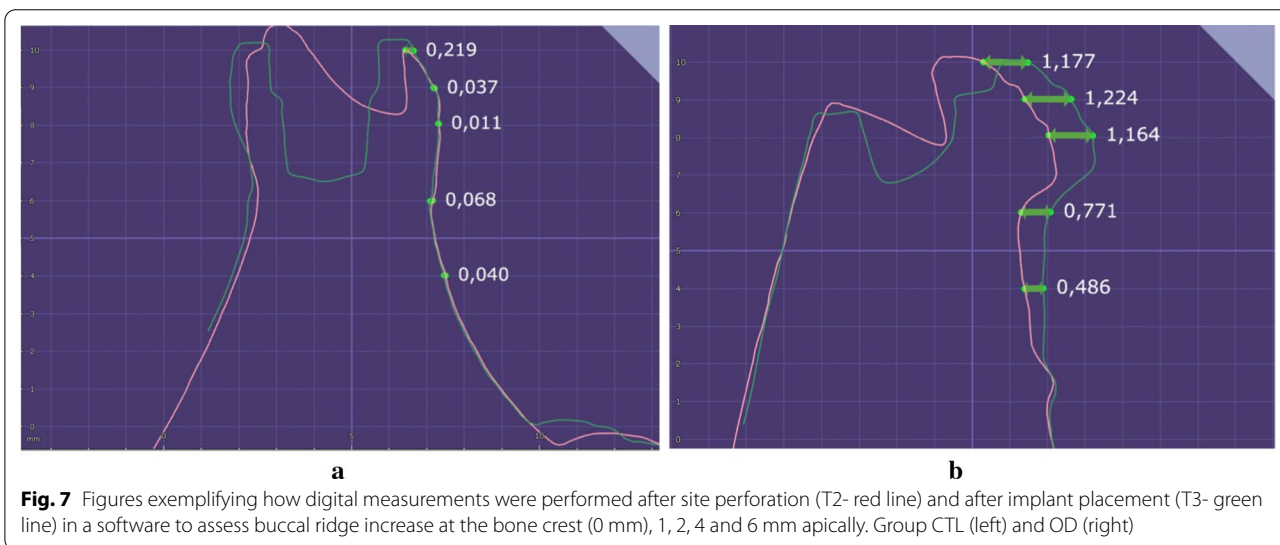
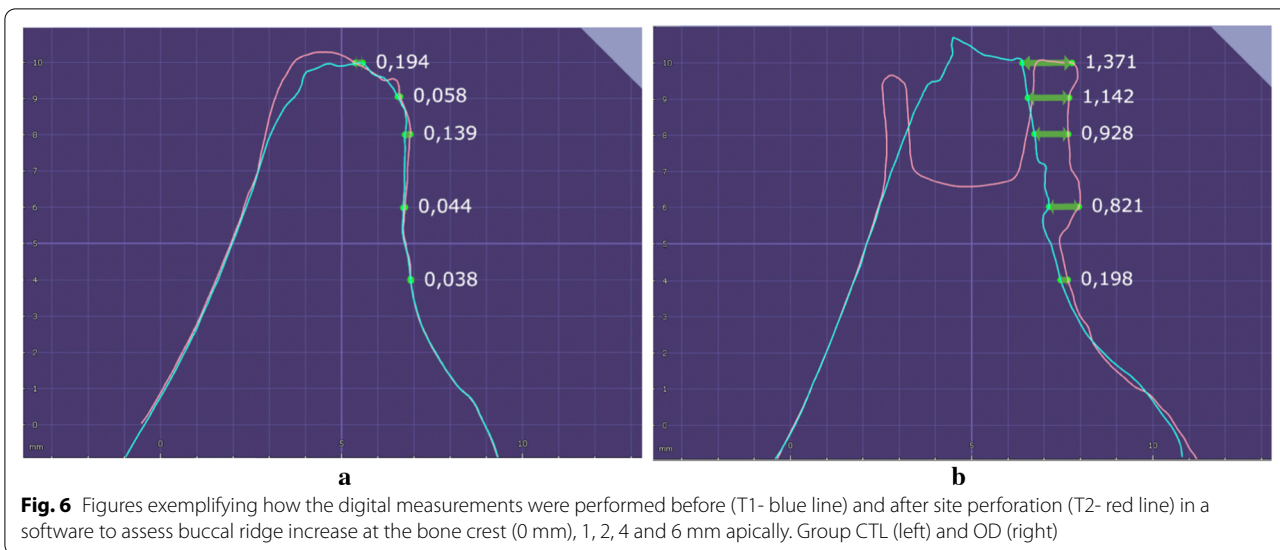
Fig. 5 Graphic of the analysis of the lingual defect in height (BDH), width (BDW) and area (BDA) after implant placement ($p \leq 0.05$ in comparison to OD group. Mann–Whitney test)

implant also positively influenced the outcome [28]. The implant design used in this study was able to further expand the buccal bone, and also reduced the occurrence of peri-implant defects. Compared to the buccal bone wall, the expansion of the lingual bone wall was limited, as its cortical plate presented lower bone plasticity and

greater thickness. Araújo et al. (2005) [29] showed that the lingual bone wall is thicker than the buccal bone wall and less prone to resorption or the formation of defects. Osseodensification promotes significant ridge expansion outcomes at sites with bone density that is below adequate [20]. In this sense, the concept of adequate has been defined with the recommendation that both cortical plates present a 1:1 ratio with a trabecular-bone core of at least 2 mm [10–15].

It has been shown that tapered implants with non-cutting threads combined with hand osteotomes are able to provide higher insertion torque and ridge expansion, especially in esthetically demanding areas [30, 31]. There are some biological, clinical and patient concerns about using such osteotomes. Ridge expansion with osteotomes may require the use of mallets, which is a more invasive and traumatic procedure and presents reduced expansive control, greater risk of bone fracture, and more patient complaints [13]. Some clinical studies have even shown that expansion with osteotomes leads to delayed healing of the implant site [32, 33]. Therefore, osseodensification has been reported to improve implant procedures in ridges with limited bone quantity or quality [19, 20].

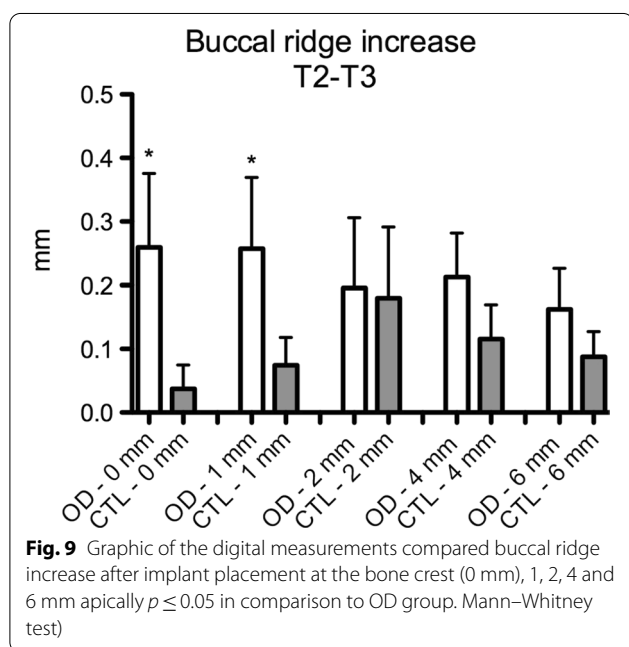
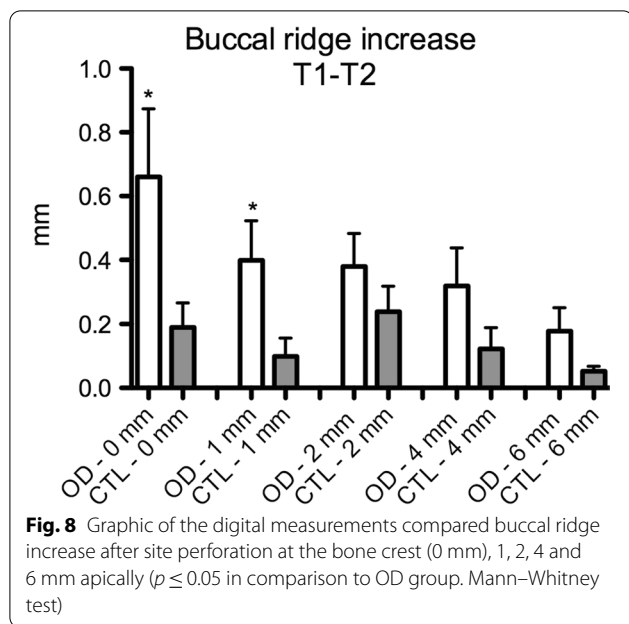
A thin buccal bone plate has been associated with a greater risk of resorption and soft tissue recession [34]. Bone grafting may not be avoided in such situations, but osseodensification can reduce the occurrence



of buccal peri-implant defects, thus allowing simultaneous implant installation and bone grafting. When the implant is surrounded by native bone, it is speculated that the healing time of the implant is shortened. A longer time would usually be needed if there was a bone dehiscence that required bone grafting involving the implant surface. Complete buccal bone regeneration after bone grafting is influenced by the site anatomy and the size of the peri-implant bone defect [8]. Osseodensification can even be performed in extraction sockets, allowing immediate implant installation with increased primary stability [35] and reducing the need for further invasive procedures. Onlay grafts performed at posterior sites to increase ridge thickness

prior to implant installation have been associated with greater trauma and postoperative complications [7].

In the present study, we scanned the ridge and performed linear 3D measurements. This would be more complicated to perform in human clinical studies. Intraoral scanning at sites that present fluids can be challenging, especially whenever there is constant bleeding [36]. However, the literature presents the results of other analyses that also support the present results. Koutozis et al. (2019) [20] performed clinical analog measurements of the alveolar ridge thickness with bone calipers pre and post osseodensification in humans and showed that it increased whenever osseodensification was performed. As shown in our study, analog evaluation can provide



viable data as there were no major differences in the analog or digital evaluation of the ridge thickness 1 mm below crestal level.

Buccal and lingual bone fenestration defects are commonly found in human sockets. Nimigean et al. [37] reported that bone dehiscences were detected in almost 55% of human skulls, and the defects in the mandible accounted for more than 70% of these dehiscences. After tooth extraction, it can be expected that sockets

that present loss of one of the bone walls will present reduced ridge width after healing [38]. Bone expansion provided by osseodensification is a simplified technique to improve the implant site. Osseodensification promotes alveolar ridge expansion at the osteotomy site [13], preventing bone dehiscence after implant installation.

One could speculate that cone beam computed tomography could be performed to analyze the increase in ridge volume, but there are concerns regarding the threshold needed for the detection of a thin buccal bone wall in contact with a metal implant, which often leads to significant artefacts in the images [39, 40]. This in vitro animal study presented limitations such as the lack of a sample size calculation and, since it was performed in fresh pig jaws and these could present anatomical variations in the alveolar ridge. The impact of such alterations could be reduced by a split mouth study design while providing important data about how osseodensification performs in mandibles. More clinical studies with appropriate sample size are needed to further compare the potential of osseodensification to improve clinical parameters and reduce surgical morbidity. The available data concerning osseodensification presents interesting outcomes that could lead to better clinical and biological outcomes by changing how the implant site is prepared in a simplified manner [20, 22, 24].

Conclusion

Osseodensification increased ridge thickness by bone expansion and reduced buccal bone defects after implant installation.

Abbreviations

CTL: Conventional drilling with cutting burs; OD: Osseodensification with Densah® burs.

Acknowledgements

Thanks to S.I.N. Implant System for providing the implants and Welfare Dental Instruments for the Densah® burs.

Author contributions

Concept and design: FF, RSN, EMJ; Data acquisition: FF, RSN, VP, NN, BG, FJBB, EM; Analysis and interpretation: FF, RSN, BG, FJBB; Drafting and editing of manuscript: FF, VP, NN, BG, FJBB, RSN, EMJ. All authors read and approved the final manuscript.

Funding

The authors received no financial support for the research, authorship, or publication of this article.

Availability of data and materials

All data generated in this study are included in this article.

Declarations

Ethical approval and consent to participate

This study was approved by the Animal Ethics Committee of the Araraquara Dental School FOAr—Unesp under protocol 20/2019.

Consent for publication

Not applicable.

Competing interests

The authors, Fausto Frizzera, Rubens Spin-Neto, Victor Padilha, Nicolas Nicchio, Bruna Ghiraldini, Fabio José Barbosa Bezerra and Elcio Marcantonio Jr, declare that they have no competing interests.

Author details

¹FAESA University Center, Vitória, Brazil. ²Aarhus University, Department of Dentistry and Oral Health, Aarhus, Denmark. ³Brazilian Dental Association at Espírito Santo, Serra, Brazil. ⁴São Paulo State University (UNESP), School of Dentistry, Department of Diagnostic and Surgery, Araraquara, Brazil. ⁵Dental Research Division, School of Dentistry, Paulista University, São Paulo, Brazil. ⁶São Paulo State University (UNESP), Department of Chemical and Biological Sciences, Institute of Biosciences, Botucatu, Brazil.

Received: 1 February 2022 Accepted: 19 May 2022

Published online: 13 June 2022

References

- Slagter KW, Meijer HJ, Bakker NA, Vissink A, Raghoobar GM. Immediate Single-tooth implant placement in bony defects in the esthetic zone: a 1-year randomized controlled trial. *J Periodontol*. 2016;87(Suppl 6):619–29.
- Domínguez GC, Fernández DA, Calzavara D, Fábrega JG. Immediate placement and restoration of implants in the esthetic zone: trimodal approach therapeutic options. *Int J Esthet Dent*. 2015;10(Suppl 1):100–21.
- Schropp L, Wenzel A, Kostopoulos L, Karring T. Bone healing and soft tissue contour changes following single-tooth extraction: a clinical and radiographic 12-month prospective study. *Int J Periodontics Restorative Dent*. 2003;23:313–23.
- Spin-Neto R, Stavropoulos A, Coletti FL, Faeda RS, Pereira LAVD, Marcantonio E Jr. Graft incorporation and implant osseointegration following the use of autologous and fresh-frozen allogeneic block bone grafts for lateral ridge augmentation. *Clin Oral Implants Res*. 2014;25(Suppl 2):226–33.
- Felice P, Soardi E, Piattelli M, Jacotti M, Esposito M. Immediate non-occlusal loading of immediate post-extractive versus delayed placement of single implants in preserved sockets of the anterior maxilla: 4-month post-loading results from a pragmatic multicentre randomised controlled trial. *Eur J Oral Implantol*. 2011;4(Suppl 4):329–44.
- Frizzera F, de Freitas RM, Muñoz-Chávez OF, Cabral G, Shibli JA, Marcantonio E Jr. Impact of soft tissue grafts to reduce peri-implant alterations after immediate implant placement and provisionalization in compromised sockets. *Int J Periodontics Restorative Dent*. 2019;39(Suppl 3):381–9.
- Pereira RS, Pavelski MD, Griza GL, Boos FBJ, Hochuli-Vieira E. Prospective evaluation of morbidity in patients who underwent autogenous bone-graft harvesting from the mandibular symphysis and retromolar regions. *Clin Implant Dent Relat Res*. 2019;21(Suppl 4):753–7.
- Frizzera F, Shibli JA, Marcantonio Jr. *Estética integrada em Periodontia e Implantodontia*. Nova Odessa: Napoleão Quintessence Publishing; 2018. p. 464.
- Kan JYK, Rungcharassaeng K, Deflorian M, Weinstein T, Wang HL, Testori T. Immediate implant placement and provisionalization of maxillary anterior single implants. *Periodontol*. 2000;2018(77 Suppl 1):197–212.
- Huwais S. Fluted osteotomy and surgical method for use. 2013. US Patent Application US2013/0004918.
- Lahens B, Lopez CD, Neiva RF, Bowers MM, Jimbo R, Bonfante EA, et al. The effect of osseodensification drilling for endosteal implants with different surface treatments: a study in sheep. *J Biomed Mater Res B Appl Biomater*. 2019;107(3):615–23.
- Alifarag AM, Lopez CD, Neiva RF, Tovar N, Witek L, Coelho PG. Atemporal osseointegration: early biomechanical stability through osseodensification. *J Orthop Res*. 2018;36(Suppl 9):2516–23.
- Huwais S, Meyer E. A novel osseous densification approach in implant osteotomy preparation to increase biomechanical primary stability, bone mineral density, and bone-to-implant contact. *Int J Oral Maxillofac Implants*. 2017;32:27–36.
- Huwais S, Mazor Z, Ioannou AL, Gluckman H, Neiva R. A multicenter retrospective clinical study with up-to-5-year follow-up utilizing a method that enhances bone density and allows for transcrestal sinus augmentation through compaction grafting. *Int J Oral Maxillofac Implants*. 2018;33(Suppl 6):1305–11.
- Trisi P, Berardini M, Falco A, Vulpiani MP. New osseodensification implant site preparation method to increase bone density in low-density bone. *Implant Dent*. 2016;25:24–31.
- Bertollo N, Walsh WR. Drilling of bone: Practicality, limitations and complications associated with surgical drill bits. In: Klika V, editor. *Biomechanics in Application*. InTech; 2011. p. 45–82.
- Slete FB, Olin P, Prasad H. Histomorphometric comparison of 3 osteotomy techniques. *Implant Dent*. 2018;27(Suppl 4):424–8.
- Oliveira PGFP, Bergamo ETP, Neiva R, Bonfante EA, Witek L, Tovar N, et al. Osseodensification outperforms conventional implant subtractive instrumentation: a study in sheep. *Mater Sci Eng C Mater Biol Appl*. 2018;90:300–7.
- Tretto PHW, Fabris V, Cericato GO, Sarkis-Onofre R, Bacchi A. Does the instrument used for the implant site preparation influence the bone-implant interface? A systematic review of clinical and animal studies. *Int J Oral Maxillofac Surg*. 2019 pii: S0901–5027(18)30135–8.
- Koutouzis T, Huwais S, Hasan F, Trahan W, Waldrop T, Neiva R. Alveolar ridge expansion by osseodensification-mediated plastic deformation and compaction autografting: a multicenter retrospective study. *Implant Dent*. 2019;28(Suppl 4):349–55.
- Elsayyad AA, Osman RB. Osseodensification in implant dentistry: a critical review of the literature. *Implant Dent*. 2019;28(Suppl 3):306–12.
- Pikos MA, Miron RJ. To drill or to densify? clinical indications for the use of osseodensification. *Compend Cont Educ Dent*. 2019;40(Suppl 5):276–81.
- Witek L, Neiva R, Alifarag A, Shahraki F, Sayah G, Tovar N, et al. Absence of healing impairment in osteotomies prepared via osseodensification drilling. *Int J Periodontics Restorative Dent*. 2019;39(Suppl 1):65–71.
- Lahens B, Lopez CD, Neiva RF, Bowers MM, Jimbo R, Bonfante EA, et al. The effect of osseodensification drilling for endosteal implants with different surface treatments: a study in sheep. *J Biomed Mater Res B Appl Biomater*. 2019;107(3):615–23.
- Sapata VM, Sanz-Martín I, Hämmerle CHF, Cesar Neto JB, Jung RE, Thoma DS. Profilmometric changes of peri-implant tissues over 5 years: A randomized controlled trial comparing a one- and two-piece implant system. *Clin Oral Implants Res*. 2018;29(8):864–72.
- Pjetursson BE, Thoma D, Jung R, Zwahlen M, Zembic A. A systematic review of the survival and complication rates of implant-supported fixed dental prostheses (FDPs) after a mean observation period of at least 5 years. *Clin Oral Implants Res*. 2012;6:22–38.
- Cheng AW, Berridge JP, McGary RT, Ercley KJ, Johnson TM. The extraction socket management continuum: a hierarchical approach to dental implant site development. *Clin Adv Periodontics*. 2019;9(2):91–104.
- Kao DW, Fiorellini JP. Comparison of ridge expansion and ridge splitting techniques for narrow alveolar ridge in a Swine cadaver model. *Int J Periodontics Restorative Dent*. 2015;35(3):44–9.
- Araújo MG, Sukekava F, Wennström JL, Lindhe J. Ridge alterations following implant placement in fresh extraction sockets: an experimental study in the dog. *J Clin Periodontol*. 2005;32(6):645–52.
- Dene L, Condos S. Ridge expansion and immediate implant placement in the esthetic zone. *N Y State Dent J*. 2010;76(2):28–31.
- Silverstein LH, Kurtzman GM, Moskowitz E, Kurtzman D, Hahn J. Aesthetic enhancement of anterior dental implants with the use of tapered osteotomes and soft tissue manipulation. *J Oral Implantol*. 1999;25(1):18–22.
- Stavropoulos A, Nyengaard JR, Lang NP, Karring T. Immediate loading of single SLA implants: drilling versus osteotomes for the preparation of the implant site. *Clin Oral Implants Res*. 2008;19:55–65.
- Büchter A, Lieinheinz J, Wiesmann HP, Kersken J, Nienkemper M, Weyhrother HV, et al. Biological and biomechanical evaluation of bone remodelling and implant stability after using an osteotomy technique. *Clin Oral Impl Res*. 2005;16:1–8.
- Benic GI, Ge Y, Gallucci GO, Jung RE, Schneider D, Hämmerle CHF. Guided bone regeneration and abutment connection augment the buccal soft tissue contour: 3-year results of a prospective comparative clinical study. *Clin Oral Implants Res*. 2017;28(2):219–25.
- Rosa JCM, Rosa ACPO, Huwais S. Use of the Immediate dentoalveolar restoration technique combined with osseodensification in periodontally

- compromised extraction sites. *Int J Periodontics Restorative Dent*. 2019;39(4):527–34.
36. Flügge TV, Schlager S, Nelson K, Nahles S, Metzger MC. Precision of intraoral digital dental impressions with iTero and extraoral digitization with the iTero and a model scanner. *Am J Orthod Dentofacial Orthop*. 2013;144(3):471–8.
 37. Nimigean VR, Nimigean V, Bencze MA, Dimcevidi-Poesina N, Cregan R, Moraru S. Alveolar bone dehiscences and fenestrations: an anatomical study and review. *Rom J Morphol Embryol*. 2009;50(3):391–7.
 38. Kan JY, Rungcharassaeng K, Sclar A, Lozada JL. Effects of the facial osseous defect morphology on gingival dynamics after immediate tooth replacement and guided bone regeneration: 1-year results. *J Oral Maxillofac Surg*. 2007;65(7 Suppl 1):13–9.
 39. De-Azevedo-Vaz SL, Vasconcelos KF, Neves FS, Melo SLS, Campos PSF, Heiter-Neto F. Detection of periimplant fenestration and dehiscence with the use of two scan modes and the smallest voxel sizes of a cone-beam computed tomography device. *Oral Surg Oral Med Oral Pathol Oral Radiol*. 2013;115(1):121–7.
 40. Gakonyo J, Mohamedali AJ, Mungure EK. Cone beam computed tomography assessment of the buccal bone thickness in anterior maxillary teeth: relevance to immediate implant placement. *Int J Oral Maxillofac Implants*. 2018;33(4):880–7.

Publisher's Note

Springer Nature remains neutral with regard to jurisdictional claims in published maps and institutional affiliations.

Ready to submit your research? Choose BMC and benefit from:

- fast, convenient online submission
- thorough peer review by experienced researchers in your field
- rapid publication on acceptance
- support for research data, including large and complex data types
- gold Open Access which fosters wider collaboration and increased citations
- maximum visibility for your research: over 100M website views per year

At BMC, research is always in progress.

Learn more biomedcentral.com/submissions

